



**PATIENT**

Obi Knagge

**PRESENTING CLINICAL SIGNS**

1mnt history of inappetence - switched to meat rice diet (chicken/rice and egg) marked decline in demeanour in the last 4 days - lethargic/refusing to walk, no eating  
 Abnormal PE/Chem/CBC/UA Results: ammonia 150umol/L alp/alt marked elevation  
 haematology not available

**SPECIES**

Canine

**COMPUTED TOMOGRAPHY OF THE THORAX AND ABDOMEN**

A high resolution pre- and post-contrast CT study of the abdomen and a post-contrast CT study of the thorax are provided for review.

**BREED**

Whippet

**COMPUTED TOMOGRAPHIC FINDINGS**

Thorax

The bony and surrounding soft tissue structures are within normal limits.

**SEX**

A small amount of free mediastinal gas is seen.

MN

The sternal, cranial mediastinal and tracheobronchial lymph nodes are small elongated with a normal short-to-long-axis-ratio is < 0.5, the attenuation and contrast enhancement pattern is uniform and considered within normal limits.

**AGE**

5

The cardiovascular structures including the pulmonary vasculature are within normal limits.

**INTERPRETED BY**

Sebastian Schaub, DVM  
 Dr. med. vet. DipECVDI

The bronchial tree presents with regular branching and tapers uniformly towards the periphery as expected, the bronchial walls are thin and smooth. The bronchus-to-artery ratio is within normal limits.

The lung parenchyma presents the expected architecture and attenuation behavior.

**HOSPITAL NAME**

Advanced Veterinary  
 Imaging

Small incidental gas pockets are seen within the esophageal lumen, there is no evidence of abnormal dilation.

Abdomen

The serosal fat presents normal attenuation behavior. There is no evidence of peritoneal effusion or peritonitis.

**REFERRING VET**

Eamon

Both kidneys present within normal limits for size, shape and organ architecture. After contrast administration a bilaterally symmetric and uniform nephro- and pyelogram is noted.

The adrenal glands are within normal limits for size, shape and organ architecture.

**INVOICE**

56569

The spleen presents with normal shape, even surface, uniformly attenuating parenchyma and homogeneous contrast enhancement, unremarkable.

The hepatic volume is mildly decreased. The hepatic margins are smooth. The hepatic parenchyma is uniform soft tissue attenuating and contrast enhancing.

**DATE**

2-4-23

At the medial aspect of the left kidney, a bunch of small tortuous vessels is seen. Originating from the splenic vein of the caudal extremity of the spleen, a bunch of tortuous vessels is appreciated, consolidating to one vessel, draining into the left renal vein from the caudal aspect.

The pancreas is evenly contoured, the pancreatic parenchyma is homogeneous and presents



**PATIENT** uniform contrast enhancement.

Obi Knagge The position, delineation, wall and content of the gastrointestinal tract are considered within normal limits throughout.

**SPECIES** The bony and surrounding soft tissue structures reveal no abnormalities.

Canine

**COMPUTED TOMOGRAPHIC DIAGNOSIS**

- Mild microhepatica
- Multiple acquired extrahepatic portosystemic shunts

**BREED**

Whippet

**INTERPRETATION OF THE FINDINGS & FURTHER RECOMMENDATIONS**

The acquired portosystemic shunts indicate portal hypertension, likely as a sequela to primary hepatic disease – such as hepatic fibrosis/cirrhosis. Recommend hepatic biopsy for further workup.

**SEX**

MN

**AGE**

5

**INTERPRETED BY**

Sebastian Schaub, DVM  
Dr. med. vet. DipECVDI

**HOSPITAL NAME**

Advanced Veterinary  
Imaging

**REFERRING VET**

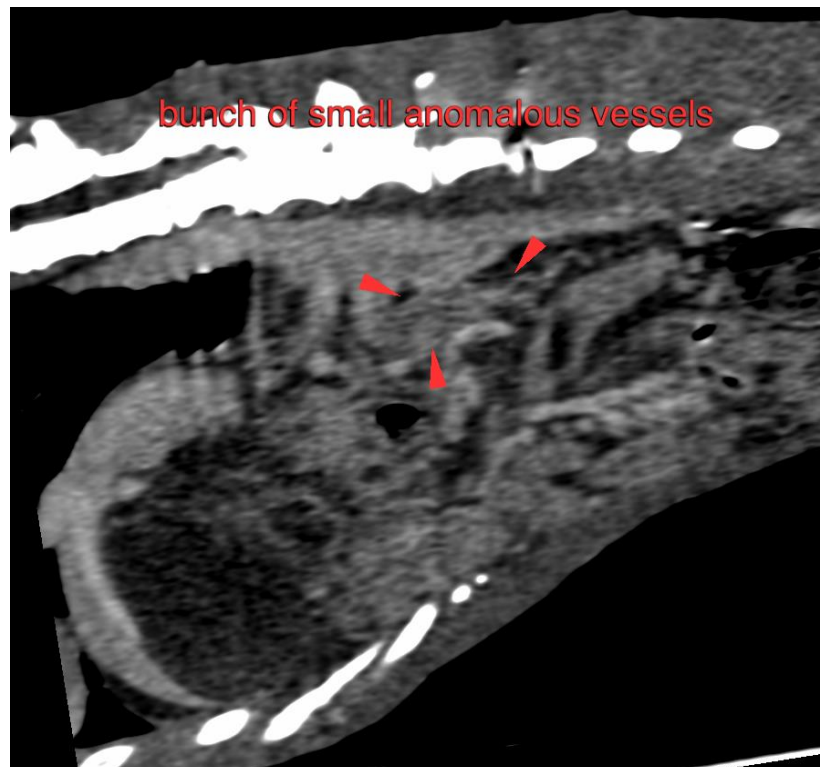
Eamon

**INVOICE**

56569

**DATE**

2-4-23





**PATIENT**

Obi Knagge

**SPECIES**

Canine

**BREED**

Whippet

**SEX**

MN

**AGE**

5

**INTERPRETED BY**

Sebastian Schaub, DVM  
Dr. med. vet. DipECVDI

**HOSPITAL NAME**

Advanced Veterinary  
Imaging

**REFERRING VET**

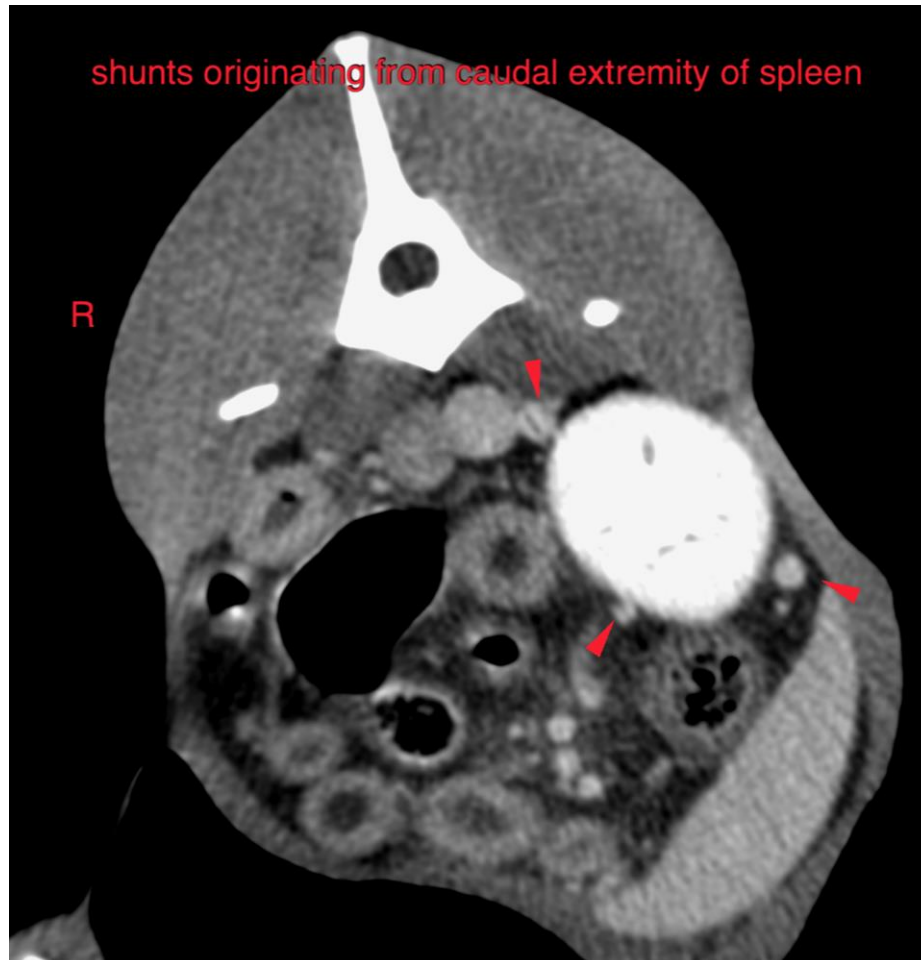Eamon

**INVOICE**

56569

**DATE**

2-4-23



The information and recommendations provided are based on the images presented by the referring veterinarian/sonographer. No evaluation can be communicated regarding pathology that was not visible in the image/video clips provided.

Thank you for this referral. If the clinical or image interpretation does not parallel your findings or if I can be of any further assistance please contact me.

**Sebastian Schaub**, Sebastian Schaub, DVM, Dr. med. vet. DipECVDI  
sebast.schaub@gmail.com