

**PATIENT**

Cheeks Russell

PRESENTING CLINICAL SIGNS

No known medical history, too young for vaccines. Patient got paw stuck in cage, presented to us with extremely swollen front left paw/shoulder area. Owner left patient in the cage, came back and noticed swollen arm. Possibly attached to the cage and pulled something.

SPECIES

Canine

RADIOGRAPHIC STUDY OF THE FRONT PAWS

Radiographs of the front paws in two orthogonal imaging planes are provided for review.

BREED

American Bully

RADIOGRAPHIC FINDINGS

There is an age related immature conformation of the osseous structures with open growth plates and incomplete ossification of the epiphysis.

Significant circumferential swelling along the left distal antebrachium and carpus is appreciated. The osseous structures appear normal.

SEX

Female

RADIOGRAPHIC DIAGNOSIS

- Soft tissue swelling left front limb, accentuated along the distal segment of the antebrachium

AGE

5 Weeks

INTERPRETATION OF THE FINDINGS & FURTHER RECOMMENDATIONS

An underlying cause for the soft tissue swelling of the left front limb is not appreciated, in combination with the history rule out underlying vascular or lymphatic injury.

INTERPRETED BY

Sebastian Schaub, DVM
Dr. med. vet. DipECVDI

HOSPITAL NAME

Wilson Road
Veterinary Clinic

REFERRING VET

Dr. Yessa

INVOICE

56567

DATE

2-4-23



PATIENT

Cheeks Russell

SPECIES

Canine

BREED

American Bully

SEX

Female

AGE

5 Weeks

INTERPRETED BY

Sebastian Schaub, DVM
Dr. med. vet. DipECVDI

HOSPITAL NAME

Wilson Road
Veterinary Clinic

REFERRING VET

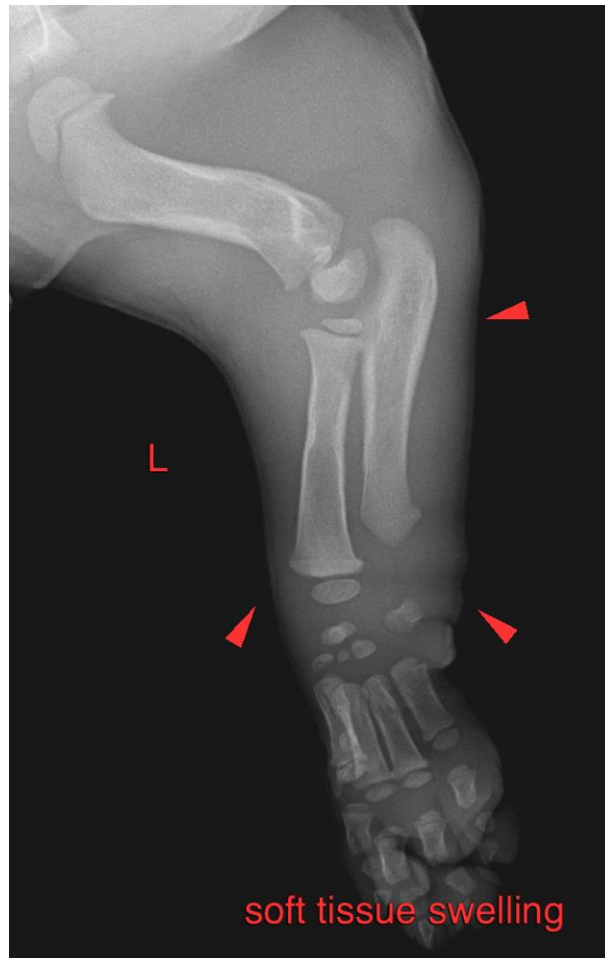
Dr. Yessa

INVOICE

56567

DATE

2-4-23



The information and recommendations provided are based on the images presented by the referring veterinarian/sonographer. No evaluation can be communicated regarding pathology that was not visible in the image/video clips provided.

Thank you for this referral. If the clinical or image interpretation does not parallel your findings or if I can be of any further assistance please contact me.

Sebastian Schaub, Sebastian Schaub, DVM, Dr. med. vet. DipECVDI
sebast.schaub@gmail.com