



PATIENT

Buddha Smith

PRESENTING CLINICAL SIGNS

Chronic ear infections for a couple of months, is being treated with Doxycycline and ear flush.

SPECIES

Feline

COMPUTED TOMOGRAPHY OF THE SKULL

A high resolution pre- and post-contrast CT study of the skull is provided for review.

BREED

Domestic Short Hair

The tooth element 106 is absent.

SEX

MN

The nasal cavity presents the expected aerated spaces between thin & even conchae and turbinates with smooth mucosal lining.

Both temporomandibular joints present congruent joint spaces with even subchondral bone surfaces and are considered within normal limits.

AGE

7 Months

The right tympanic bulla contains a moderate amount of fluid attenuating and non-contrast enhancing soft tissue material. The osseous lining of the right tympanic bulla is significantly thickened and smooth. The osseous segment of the right auditory tube is mildly distended and contains a small amount of gas. Post contrast administration, a small polypoid lesion is extending from the medial aspect of the right tympanic bulla up to the region of the tympanic membrane/into the right external ear canal. The horizontal segment of the right external ear canal contains a mild amount of fluid attenuating material.

INTERPRETED BY

Sebastian Schaub, DVM
Dr. med. vet. DipECVDI

The brain presents no deviation from normal anatomy and symmetry. The brain parenchyma is homogeneous and within normal limits for attenuation and distribution of contrast enhancement. The ventricular system is non-dilated and symmetric.

HOSPITAL NAME

Southern Oregon
Veterinary Specialty
Center

The submandibular and medial retropharyngeal lymph nodes are small and elongated with a normal short-to-long-axis-ratio is < 0.5, the attenuation and contrast enhancement pattern is uniform.

COMPUTED TOMOGRAPHIC DIAGNOSIS

REFERRING VET

Dr. Fugazzi

- Right sided chronic otitis media
- Suspect small inflammatory polyp level with the right tympanic membrane
- Right sided otitis externa
- Absent triadan 106

INTERPRETATION OF THE FINDINGS & FURTHER RECOMMENDATIONS

INVOICE

50087

The findings are consistent with right sided chronic otitis media with potential small inflammatory polyp extending up to the level of the right tympanic membrane – possibly protruding mildly into the right external ear canal. Recommend otoscopy to check the tympanic membrane for presence of a small polyp – if so traction technique can be used to remove the polyp. Otherwise, a ventral bulla osteotomy might be considered as potential treatment option and remove the inflammatory tissue.

DATE

2-4-22



PATIENT

Buddha Smith

SPECIES

Feline

BREED

Domestic Short Hair

SEX

MN

AGE

7 Months

INTERPRETED BY

Sebastian Schaub, DVM
Dr. med. vet. DipECVDI

HOSPITAL NAME

Southern Oregon
Veterinary Specialty
Center

REFERRING VET

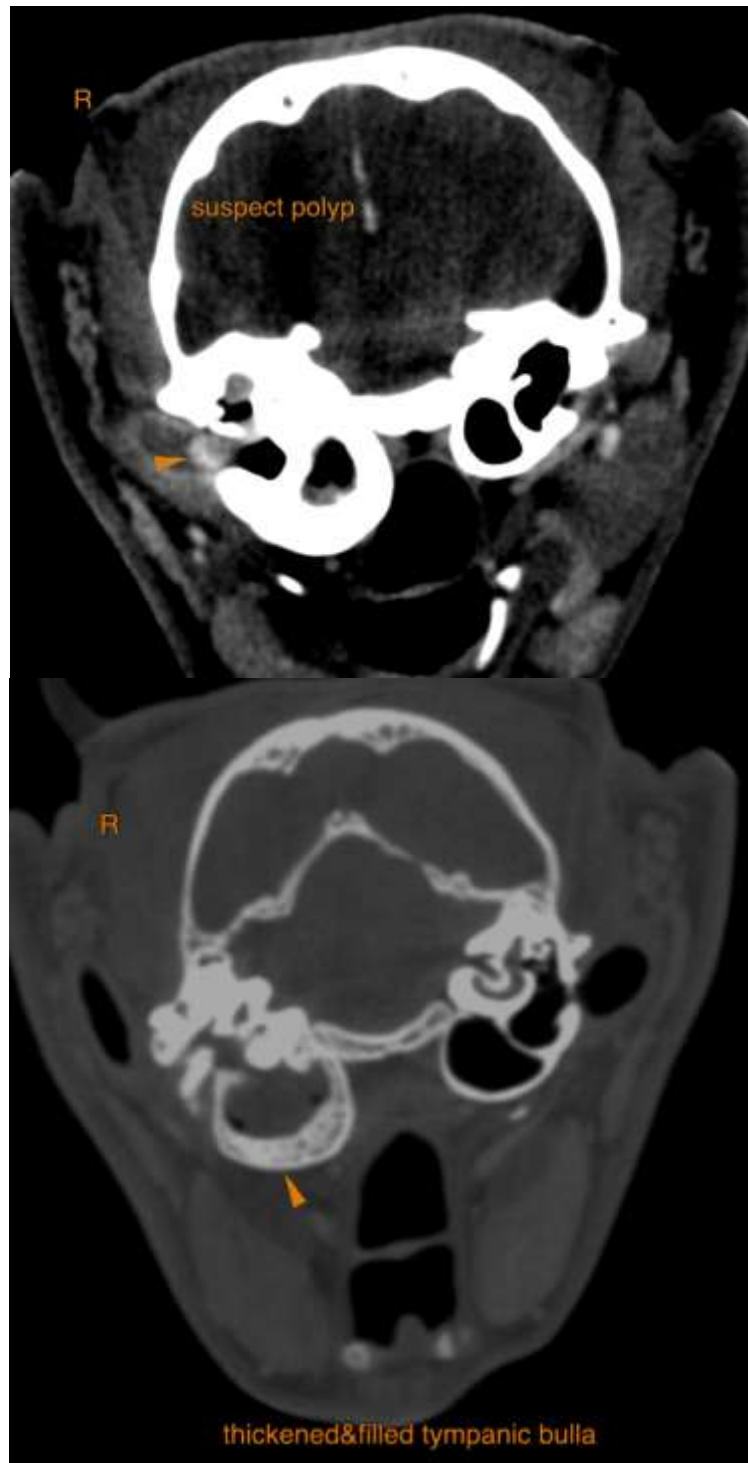
Dr. Fugazzi

INVOICE

50087

DATE

2-4-22





PATIENT

Buddha Smith

SPECIES

Feline

BREED

Domestic Short Hair

SEX

MN

AGE

7 Months

INTERPRETED BY

Sebastian Schaub, DVM
Dr. med. vet. DipECVDI

HOSPITAL NAME

Southern Oregon
Veterinary Specialty
Center

REFERRING VET

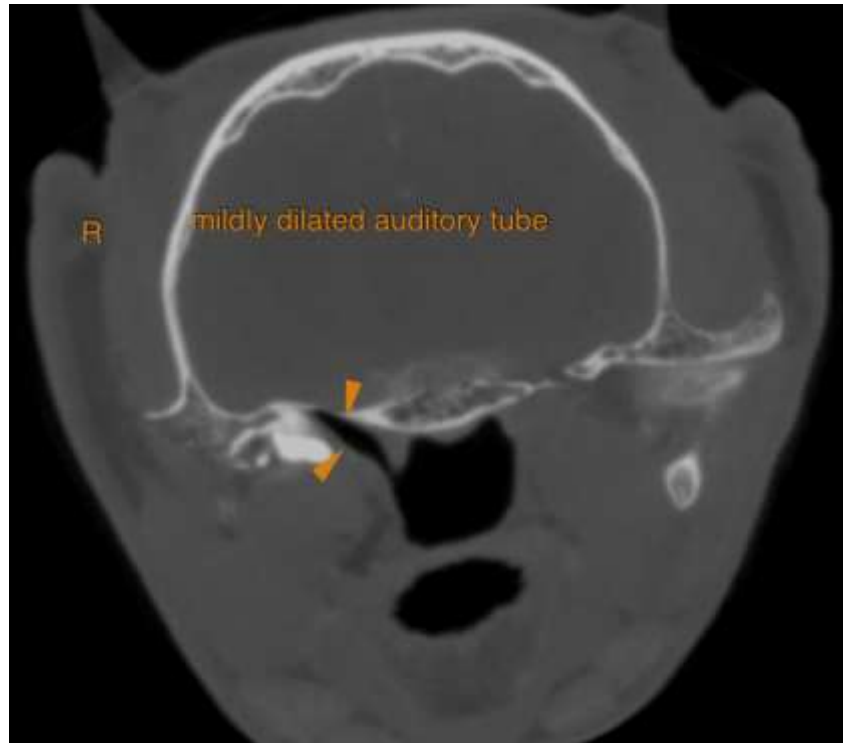
Dr. Fugazzi

INVOICE

50087

DATE

2-4-22



The information and recommendations provided are based on the images presented by the referring veterinarian/sonographer. No evaluation can be communicated regarding pathology that was not visible in the image/video clips provided.

Thank you for this referral. If the clinical or image interpretation does not parallel your findings or if I can be of any further assistance please contact me.

Sebastian Schaub, Sebastian Schaub, DVM, Dr. med. vet. DipECVDI
sebast.schaub@gmail.com