



## PATIENT

Archie Alfaro

## SPECIES

Canine

## BREED

GSD Mix

## SEX

MN

## AGE

5Y

## WEIGHT

73lbs

## INTERPRETED BY

Sebastian Schaub, DVM  
Dr. med. vet.  
DipECVDI

## IMAGING PERFORMED BY

Mallory Frois

## HOSPITAL NAME

The Pet Hospital of  
Stratford

## REFERRING VET

Dr Giuliani

## INVOICE

73596

## DATE

2-3-26

## PRESENTING CLINICAL SIGNS

History:

- just dx w/aggressive osteolytic lesion
- met check

## RADIOGRAPHIC STUDY OF THE THORAX

Radiographs of the thorax in three imaging planes are provided for review.

## RADIOGRAPHIC FINDINGS

The surrounding bony structures are within normal limits.

The extrathoracic soft tissues present homogeneous without abnormalities.

The heart is of normal size and shape; there is no evidence of cardiac chamber or vascular enlargement. The pulmonary vasculature is within normal limits.

The cranial mediastinum presents the expected soft tissue opacity. The mediastinal width is less than twice the width of the vertebral column at the same level.

The trachea is normal in diameter and presents the anticipated course. The luminal outline of the trachea is smooth.

The bronchial tree presents with thin walls and tapers uniformly towards the periphery as expected.

The lung parenchyma presents the expected architecture and opacity; the intrapulmonary vascular branching is seen up to the third order lung vessels.

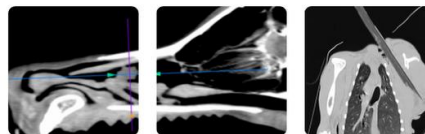
The diaphragm is well delineated with even surface and the expected mild cranial bulging of the diaphragmatic cupola.

## RADIOGRAPHIC DIAGNOSIS

- Normal thorax

## INTERPRETATION OF THE FINDINGS & FURTHER RECOMMENDATIONS

The radiographic study reveals no abnormalities and is negative for pulmonary metastatic disease.



## PATIENT

Archie Alfaro

## SPECIES

Canine

## BREED

GSD Mix

## SEX

MN

## AGE

5Y

## WEIGHT

73lbs

## INTERPRETED BY

Sebastian Schaub, DVM  
Dr. med. vet.  
DipECVDI

## IMAGING PERFORMED BY

Mallory Frois

## HOSPITAL NAME

The Pet Hospital of  
Stratford

## REFERRING VET

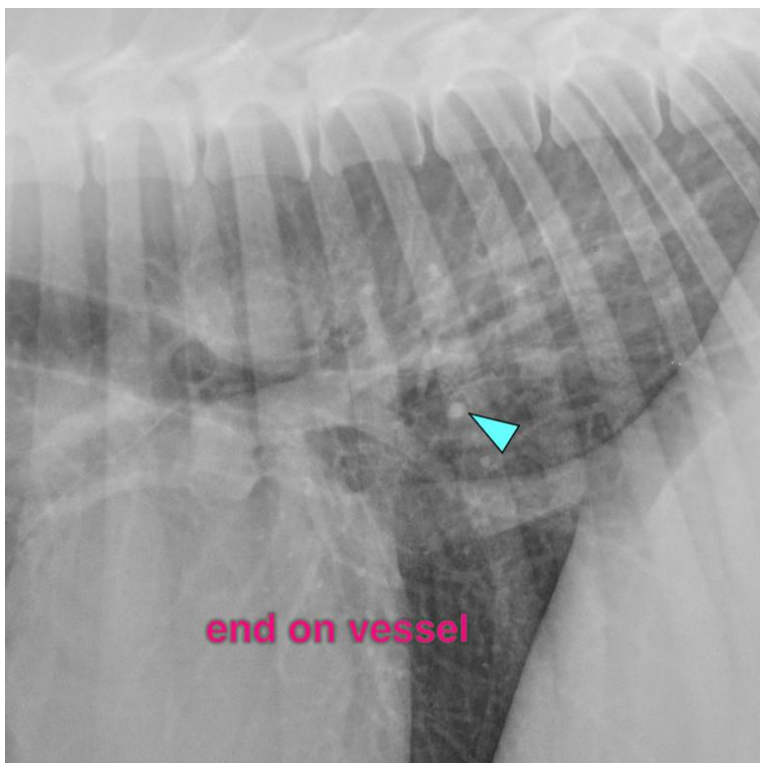
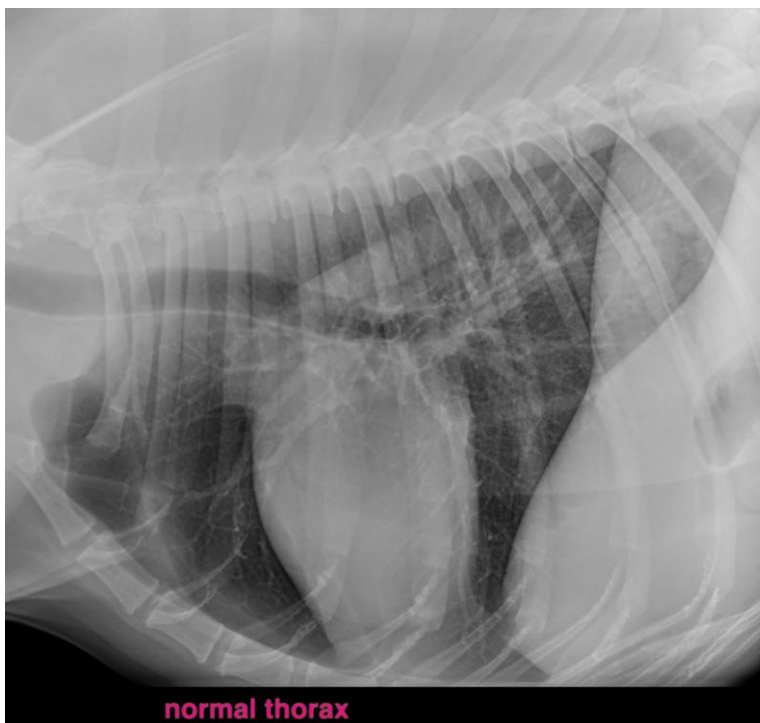
Dr Giuliani

## INVOICE

73596

## DATE

2-3-26





## PATIENT

Archie Alfaro

## SPECIES

Canine

## BREED

GSD Mix

## SEX

MN

## AGE

5Y

## WEIGHT

73lbs

## INTERPRETED BY

Sebastian Schaub, DVM  
Dr. med. vet.  
DipECVDI

## IMAGING PERFORMED BY

Mallory Frois

## HOSPITAL NAME

The Pet Hospital of  
Stratford

## REFERRING VET

Dr Giuliani

## INVOICE

73596

## DATE

2-3-26

The information and recommendations provided are based on the images presented by the referring veterinarian/sonographer. No evaluation can be communicated regarding pathology that was not visible in the image/video clips provided.

Thank you for this referral. If the clinical or image interpretation does not parallel your findings or if I can be of any further assistance please contact me.

**Sebastian Schaub**, Sebastian Schaub, DVM, Dr. med. vet. DipECVDI  
[info@sonopath.com](mailto:info@sonopath.com)