



PATIENT

May Bell Blanco

PRESENTING CLINICAL SIGNS

Chronic nasal discharge from left nostril. Current meds: Prednisone 2.5mg SID
 Abnormal PE/Chem/CBC/UA Results: WBC 19.47, NEU 16.25, HGB 21, MCH 26, MCHC 41.3, PLT 505, BUN 41

SPECIES

Canine

COMPUTED TOMOGRAPHY OF THE SKULL

A high resolution pre- and post-contrast CT study of the skull is provided for review.

BREED

Shih Tzu

COMPUTED TOMOGRAPHIC FINDINGS

The tooth elements 101, 105-110, 305, 308, 311, 405, 406, 410 and 411 are absent. A remaining root of triadan 101 is noted. Rotation of the maxillary premolar teeth is appreciated, and the alveolar crest is moderately widened. The root of triadan 204 is perforating the nasal cavity.

SEX

FS

Advanced destruction of the left nasal conchal & turbinate structures is appreciated, and a moderate amount of fluid attenuating material is attached to the nasal mucosal lining.

AGE

6 Years

Both temporomandibular joints present congruent joint spaces with even subchondral bone surfaces and are considered within normal limits.

Both tympanic bullae are aerated, the mucosal lining is not seen, the bony wall is smooth and thin. The external ear canals are within normal limits.

The brain presents no deviation from normal anatomy and symmetry. The brain parenchyma is homogeneous and within normal limits for attenuation and distribution of contrast enhancement. The ventricular system is non-dilated and symmetric.

INTERPRETED BY

Sebastian Schaub, DVM
 Dr. med. vet. DipECVDI

The submandibular and medial retropharyngeal lymph nodes are small and elongated with a normal short-to-long-axis-ratio is < 0.5, the attenuation and contrast enhancement pattern is uniform.

HOSPITAL NAME

Byram Animal Hospital

COMPUTED TOMOGRAPHIC DIAGNOSIS

- Periodontal abscess formation triadan 204 with oronasal fistula formation
- Left sided chronic destructive rhinitis
- Remaining root triadan 101
- Multiple absent teeth

REFERRING VET

Dr. Abdul-chani

INTERPRETATION OF THE FINDINGS & FURTHER RECOMMENDATIONS

The findings are consistent with periodontal abscess formation triadan 204 with oronasal fistula formation and secondary odontogenic destructive rhinitis. The findings are a plausible explanation for the presenting clinical signs. A complete dental workup with extraction of the respective tooth is recommended.

INVOICE

56565

DATE

2-3-23



PATIENT

May Bell Blanco

SPECIES

Canine

BREED

Shih Tzu

SEX

FS

AGE

6 Years

INTERPRETED BY

Sebastian Schaub, DVM
Dr. med. vet. DipECVDI

HOSPITAL NAME

Byram Animal
Hospital

REFERRING VET

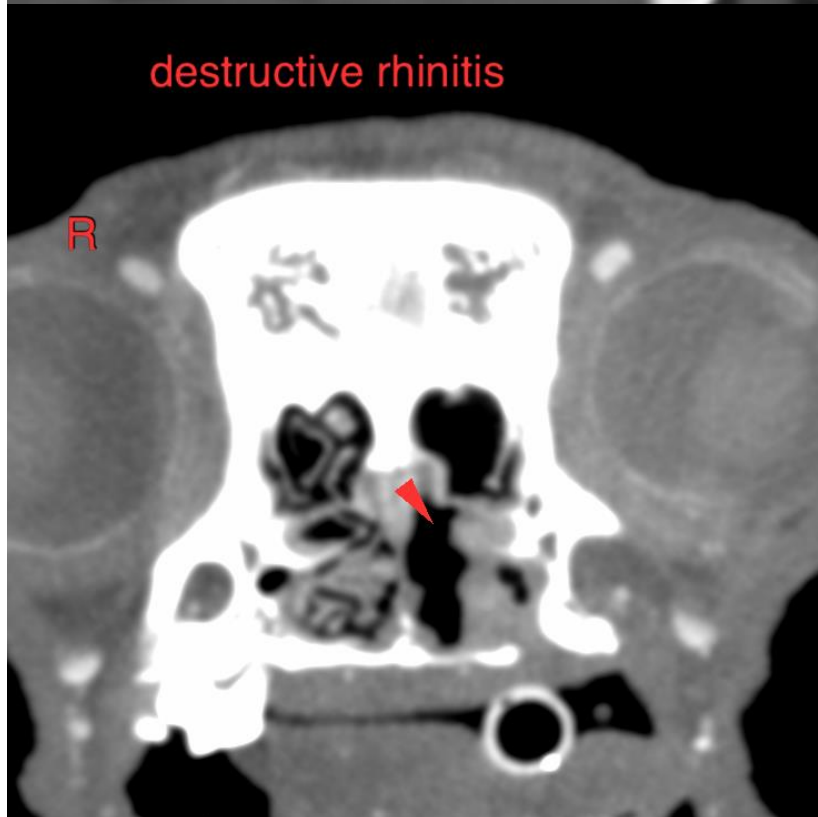
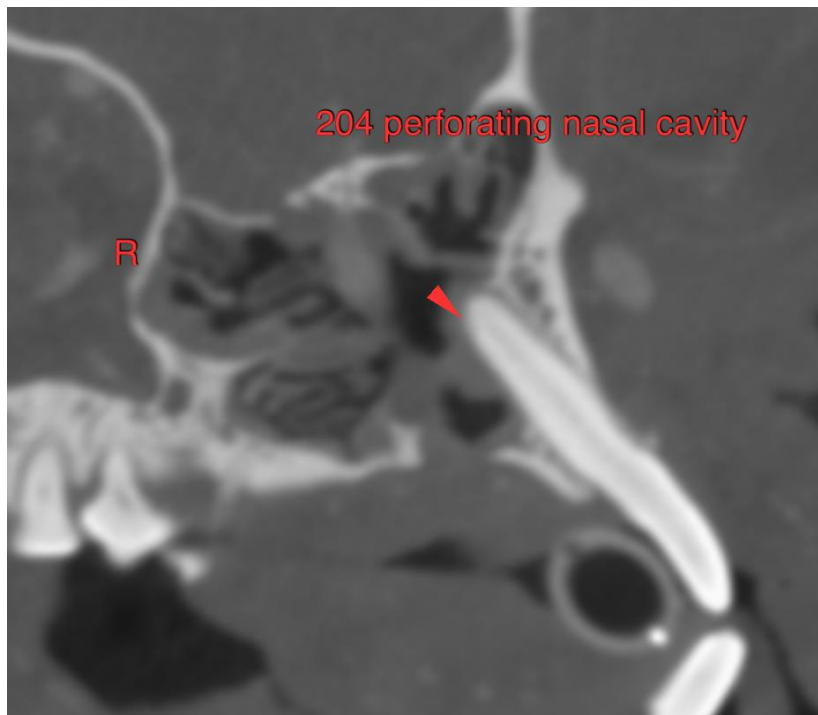
Dr. Abdul-chani

INVOICE

56565

DATE

2-3-23





PATIENT

May Bell Blanco

SPECIES

Canine

BREED

Shih Tzu

SEX

FS

AGE

6 Years

INTERPRETED BY

Sebastian Schaub, DVM
Dr. med. vet. DipECVDI

HOSPITAL NAME

Byram Animal
Hospital

REFERRING VET

Dr. Abdul-chani

INVOICE

56565

DATE

2-3-23

The information and recommendations provided are based on the images presented by the referring veterinarian/sonographer. No evaluation can be communicated regarding pathology that was not visible in the image/video clips provided.

Thank you for this referral. If the clinical or image interpretation does not parallel your findings or if I can be of any further assistance please contact me.

Sebastian Schaub, Sebastian Schaub, DVM, Dr. med. vet. DipECVDI
sebast.schaub@gmail.com