



PATIENT PRESENTING CLINICAL SIGNS

PATIENT Bailey Riddle
SPECIES Bailey presents to MVCT for a thoracic and abdominal CT. A pre- and 1 min- post contrast helical study submitted in soft tissue algorithm. Bailey has a history of mild anemia and increased ALP. Clinically normal at home other than weight bearing left front lameness. Recent thoracic radiographs show no sign of metastasis or heart disease. CT to confirm. Splenic mass found on u/s.

Canine

COMPUTED TOMOGRAPHY OF THE THORAX AND ABDOMEN

BREED

A pre- and post-contrast CT study of the thorax and abdomen in a soft tissue reconstruction provided for review.

French Bulldog

COMPUTED TOMOGRAPHIC FINDINGS

Thorax

SEX

Medial to the right latissimus dorsi muscle, a well-defined lipoma is seen.

MN

A vacuum phenomenon is seen in the joint space of the right shoulder joint.

AGE

The sternal, cranial mediastinal and tracheobronchial lymph nodes are small elongated with a normal short-to-long-axis-ratio is < 0.5, the attenuation and contrast enhancement pattern is uniform and considered within normal limits.

17

The cardiovascular structures including the pulmonary vasculature are within normal limits.

INTERPRETED BY

The bronchial tree presents with regular branching and tapers uniformly towards the periphery as expected, the bronchial walls are thin and smooth. The bronchus-to-artery ratio is within normal limits.

Sebastian Schaub, DVM
 Dr. med. vet. DipECVDI

HOSPITAL NAME

In the dorsal aspect of the cranial part of the left cranial lung lobe, a well-defined gas filled roundish lesion is visible, measuring 2.9 mm in diameter, demarcated by a thin soft tissue attenuating capsule is seen. The lung parenchyma presents the expected architecture and attenuation behavior.

Mobile Veterinary CT

Small incidental gas pockets are seen within the esophageal lumen, there is no evidence of abnormal dilation.

REFERRING VET

Abdomen

Akshay Verdema,
 DVM

The serosal fat presents normal attenuation behavior. There is no evidence of peritoneal effusion or peritonitis.

INVOICE

Both kidneys present within normal limits for size, shape and organ architecture. After contrast administration a bilaterally symmetric and uniform nephro- and pyelogram is noted.

56564

The adrenal glands are within normal limits for size, shape and organ architecture.

Both liver and spleen present with normal shape, even surface, uniformly attenuating parenchyma and homogeneous contrast enhancement, unremarkable.

DATE

The liver is normal in size and shape. The parenchyma of the left medial liver lobe presents a small (<3 mm) roundish parenchymal filling defect. The remainder of the hepatic parenchyma are uniform soft tissue attenuating and contrast enhancement.

2-3-23

The pancreas is evenly contoured, the pancreatic parenchyma is homogeneous and presents



PATIENT uniform contrast enhancement.

Bailey Riddle The position, delineation, wall and content of the gastrointestinal tract are considered within normal limits throughout.

SPECIES The bony and surrounding soft tissue structures reveal no abnormalities.

Canine

- Lipoma right thoracic wall
- Hepatic cyst
- Bulla left cranial lung lobe

BREED

French Bulldog

INTERPRETATION OF THE FINDINGS & FURTHER RECOMMENDATIONS

The CT study presents without clinically relevant abnormalities.

SEX

The splenic lesion appreciated by ultrasound cannot be appreciated in the CT study – FNA sampling can be performed to rule out malignant infiltration.

MN

AGE

17

INTERPRETED BY

Sebastian Schaub, DVM
Dr. med. vet. DipECVDI

HOSPITAL NAME

Mobile Veterinary CT

REFERRING VET

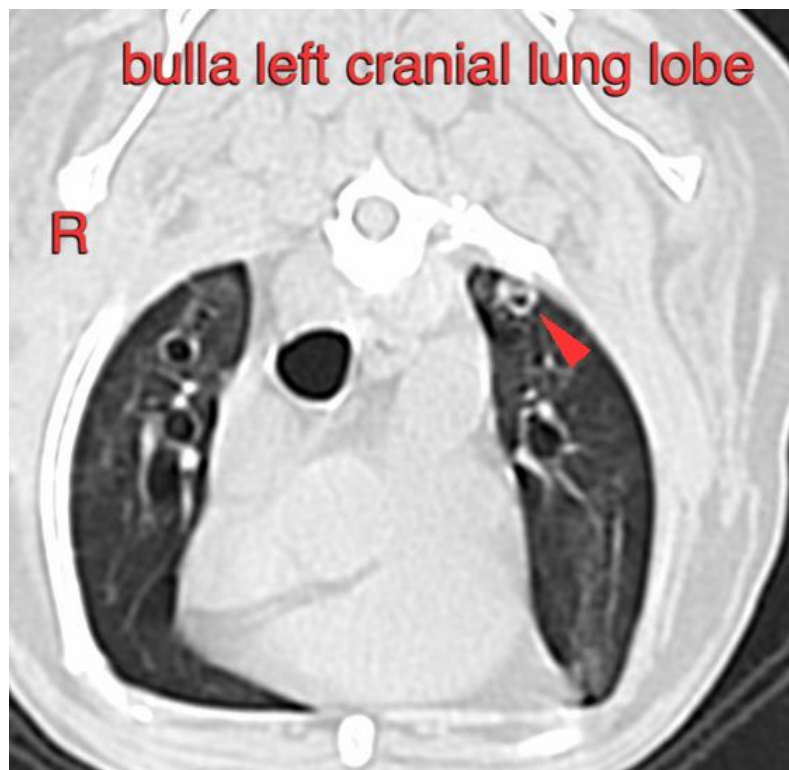
Akshay Verdema,
DVM

INVOICE

56564

DATE

2-3-23





PATIENT

Bailey Riddle

SPECIES

Canine

BREED

French Bulldog

SEX

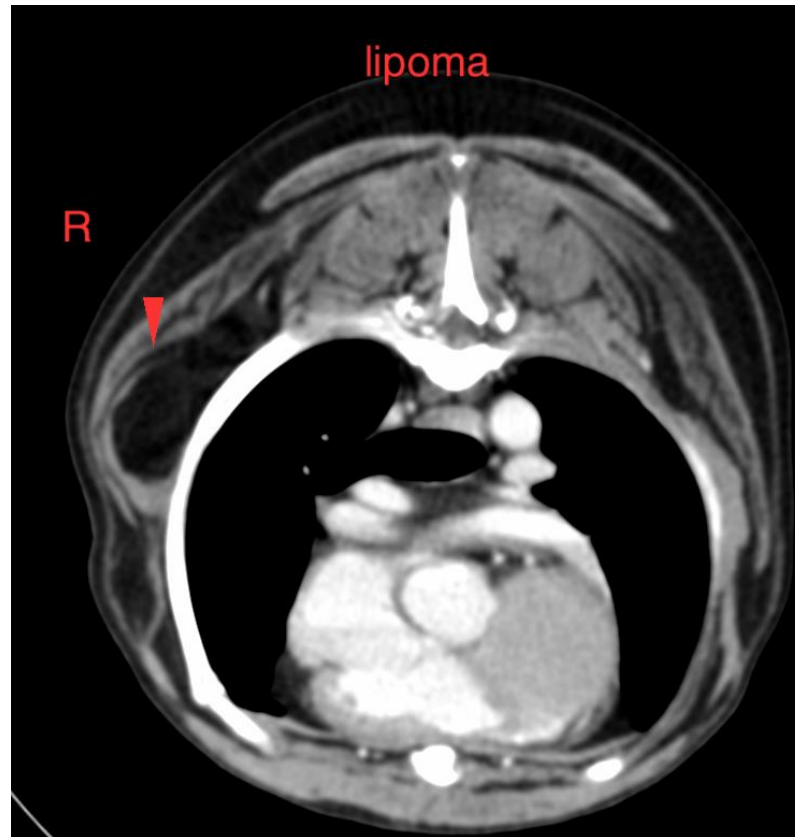
MN

AGE

17

INTERPRETED BY

Sebastian Schaub, DVM
Dr. med. vet. DipECVDI



HOSPITAL NAME

Mobile Veterinary CT

REFERRING VET

Akshay Verdem, DVM

INVOICE

56564

DATE

2-3-23

The information and recommendations provided are based on the images presented by the referring veterinarian/sonographer. No evaluation can be communicated regarding pathology that was not visible in the image/video clips provided.

Thank you for this referral. If the clinical or image interpretation does not parallel your findings or if I can be of any further assistance please contact me.

Sebastian Schaub, Sebastian Schaub, DVM, Dr. med. vet. DipECVDI
sebast.schaub@gmail.com