



PATIENT PRESENTING CLINICAL SIGNS

PATIENT Jasper Vasiliu
SPECIES Canine
BREED Mixed
SEX Male
AGE 5 Years

History: Jasper is a 5-year-old intact male mixed breed presented with limping (right hind leg) As per owner's statements: - Jasper hit his right hind leg on door - Jasper hit his right hind leg on Tuesday and has not been putting any weight on it - He has been limping on the examination today he was not weight bearing in the right hind leg and was toe touching. He was tender on the palpation of stifle joint, although the drawer test was negative. He also has a lateral deviation of his left front leg that is something that he had had for long time (angular limb deformity).

RADIOGRAPHIC STUDY OF THE FRONT & HIND PAWS

A complete set of radiographs of the front & hind paws is provided for review.

RADIOGRAPHIC FINDINGS

The radius bilaterally presents a procurvatum conformation.

A small osseous spur is protruding from the lateral surface of the metaphyseal region of the 2nd metacarpal bone of the left front limb.

The right stifle joint presents a mild intracapsular soft tissue swelling. The osseous margins of both stifle joints are smooth.

The osseous and soft tissue structures of the hind paws are within normal limits.

INTERPRETED BY RADIOGRAPHIC DIAGNOSIS

Sebastian Schaub,
 DVM Dr. med. vet.
 DipECVDI

- Mild articular swelling right stifle joint
- Small exostosis distal metaphysis second metacarpal bone left front paw
- Procurvatum conformation radius bilaterally
- Normal hind paws

HOSPITAL NAME INTERPRETATION OF THE FINDINGS & FURTHER RECOMMENDATIONS

Beaches Fallingbrook
 VC

The mild articular swelling of the right stifle joint can be degenerative, traumatic or inflammatory in origin. The most common cause is pathology of the cranial cruciate ligament ± meniscal pathology.

REFERRING VET A positive drawer sign or tibial compression test under general anesthesia can be used for further definition.

Matt Haight

INVOICE

13746

DATE

2/3/22



PATIENT

Jasper Vasiliu

SPECIES

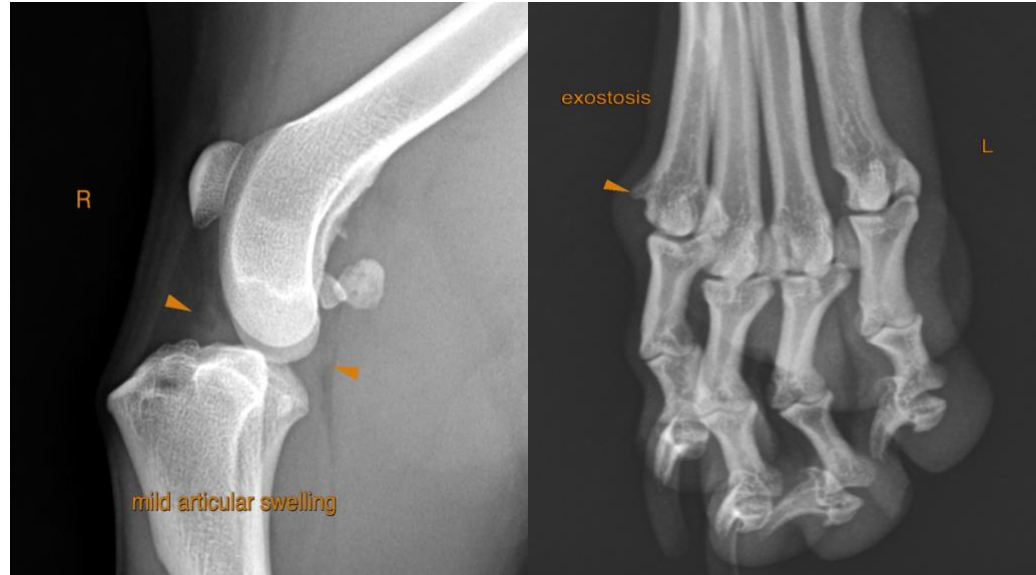
Canine

BREED

Mixed

SEX

Male



AGE

5 Years

The information and recommendations provided are based on the images presented by the referring veterinarian/sonographer. No evaluation can be communicated regarding pathology that was not visible in the image/video clips provided.

Thank you for this referral. If the clinical or image interpretation does not parallel your findings or if I can be of any further assistance please contact me.

INTERPRETED BY

Sebastian Schaub,
DVM Dr. med. vet.
DipECVDI

Sebastian Schaub, Sebastian Schaub, DVM, Dr. med. vet. DipECVDI
sebast.schaub@gmail.com

HOSPITAL NAME

Beaches Fallingbrook
VC

REFERRING VET

Matt Haightat

INVOICE

13746

DATE

2/3/22