



PATIENT PRESENTING CLINICAL SIGNS

Benjamin Shammah History: possible parathyroid mass. Ionized calcium was high.
Abnormal PE/Chem/CBC/UA Results:

SPECIES COMPUTED TOMOGRAPHIC STUDY OF THE NECK & THORAX

Canine A high-resolution plain CT study of the neck & thorax are provided for review.

COMPUTED TOMOGRAPHIC FINDINGS

BREED

American Staffordshire Terrier

Both external ear canals present a moderately thickened wall with moderate shell-like mineralization. The thyroid glands are not appreciated.

Multifocal along the thoracic spine, moderate spondylosis formation is seen.

SEX

Neutered Male

In the subcutaneous tissue along the left ventrolateral thoracic wall, a well-defined soft tissue attenuating and homogeneous contrast enhancing mass, measuring 13.8 x 5.4 x 15.0 cm in size is noted.
The superficial cervical lymph nodes and axillary lymph nodes bilaterally are prominent.

AGE

11 Years

An ovoid shaped lipoma is seen along the right cranial abdominal wall, measuring 7.5 x 3.0 x 7.0 cm in size.

INTERPRETED BY

Sebastian Schaub,
DVM Dr. med. vet.
DipECVDI

The sternal, cranial mediastinal and tracheobronchial lymph nodes are small elongated with a normal short-to-long-axis-ratio is < 0.5, the attenuation and contrast enhancement pattern is uniform and considered within normal limits.

The cardiovascular structures including the pulmonary vasculature are within normal limits.

HOSPITAL NAME

Animal Surgical Center

The bronchial tree presents with regular branching and tapers uniformly towards the periphery as expected, the bronchial walls are thin and smooth. The bronchus-to-artery ratio is within normal limits.

The cranioventral aspects of the lung parenchyma are consolidated, presenting a moderately decreased volume. The lung parenchyma presents the expected architecture and attenuation behavior.

REFERRING VET

East Bay Vet Hospital

Small incidental gas pockets are seen within the esophageal lumen, there is no evidence of abnormal dilation.

COMPUTED TOMOGRAPHIC DIAGNOSIS

INVOICE

13732

- Lymphadenopathy axillary and superficial cervical lymph nodes bilaterally
- Soft tissue mass left lateroventral thoracic
- Lipoma right thoracic wall
- Regions of compression atelectasis ventral dependent aspects of the lung

DATE

2/3/22



PATIENT

Benjamin Shammah

- Chronic otitis externa with dystrophic mineralization
- Spondylosis deformans
- No evidence of pulmonary metastatic disease

INTERPRETATION OF THE FINDINGS & FURTHER RECOMMENDATIONS

SPECIES

Canine

The current CT study presents no evidence of enlargement of the parathyroid glands and the thyroid glands are not specifically delineated overall in the current plain CT. If not done so yet, recommend FNA sampling of the large subcutaneous mass at the left ventral thoracic wall as well as the prominent lymph nodes to rule out underlying round cell neoplasia. Rule out mass of the anal sacs as well.

BREED

American Staffordshire Terrier

If lab work is highly suggestive for pathology of the parathyroid glands, recommend repeating the CT study of the neck, including a post contrast study, to allow differentiation between the anatomical structures of the neck.

SEX

Neutered Male

AGE

11 Years

INTERPRETED BY

Sebastian Schaub,
DVM Dr. med. vet.
DipECVDI

HOSPITAL NAME

Animal Surgical
Center

REFERRING VET

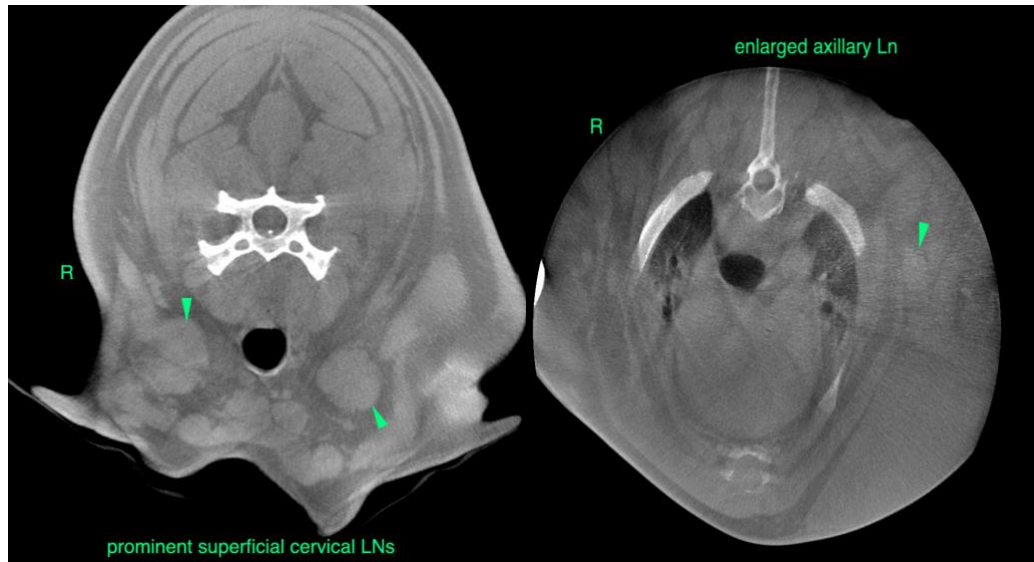
East Bay Vet Hospital

INVOICE

13732

DATE

2/3/22





PATIENT

Benjamin Shammah

SPECIES

Canine

BREED

American
Staffordshire Terrier

SEX

Neutered Male

AGE

11 Years

INTERPRETED BY

Sebastian Schaub,
DVM Dr. med. vet.
DipECVDI

HOSPITAL NAME

Animal Surgical
Center

REFERRING VET

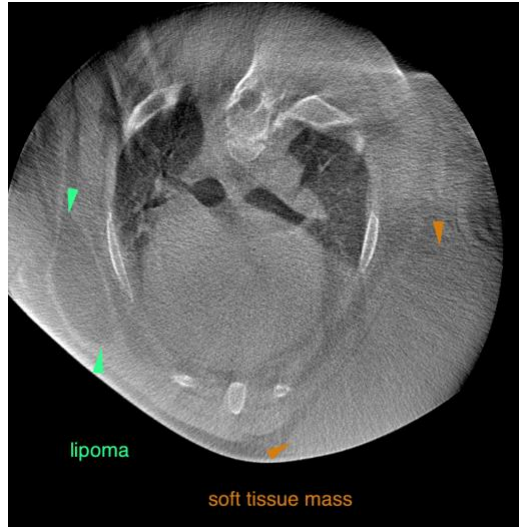
East Bay Vet Hospital

INVOICE

13732

DATE

2/3/22



The information and recommendations provided are based on the images presented by the referring veterinarian/sonographer. No evaluation can be communicated regarding pathology that was not visible in the image/video clips provided.

Thank you for this referral. If the clinical or image interpretation does not parallel your findings or if I can be of any further assistance please contact me.

Sebastian Schaub, Sebastian Schaub, DVM, Dr. med. vet. DipECVDI
sebast.schaub@gmail.com