

**PATIENT**

Pandora Hamilton

SPECIES

Canine

BREEDCorgi - Pembroke
Welsh**SEX**

F

AGE

7 Years, 7 Months

INTERPRETED BYSebastian Schaub, DVM
Dr. med. vet. DipECVDI**HOSPITAL NAME**State Avenue Vet
Clinic**REFERRING VET**

Dr. Raul Casas

INVOICE

57002

DATE

2-28-23

PRESENTING CLINICAL SIGNS

Has dried discharge on left nostril on ventral edge and commissure; with mucus just inside nostril edge; sedated; cleaned nostril; no significant discharge from the nasal passages; No immediate obvious abnormalities to explain the nasal discharge were apparent. obtained CT and performed rhinoscopy/biopsy (sent-out, waiting for results) Rhinoscopy of the L nasal passages was performed. No masses, FBs or any other sig abnormalities were identified. The edge of the nostril appeared slightly moist and when squeezed it oozed some fluid.

COMPUTED TOMOGRAPHY OF THE SKULL

A high resolution plain CT study of the skull is provided for review.

COMPUTED TOMOGRAPHIC FINDINGS

Triadan 208, 311, 401 and 411 are absent. A remaining root of triadan 301 is absent.

The nasal cavity presents the expected aerated spaces between thin & even conchae and turbinates with smooth mucosal lining.

Both temporomandibular joints present congruent joint spaces with even subchondral bone surfaces and are considered within normal limits.

Both tympanic bullae are aerated, the mucosal lining is not seen, the bony wall is smooth and thin. The external ear canals are within normal limits.

COMPUTED TOMOGRAPHIC DIAGNOSIS

- Absent triadan 208, 311, 401 and 411 with remaining root of triadan 401
- Normal upper airways

INTERPRETATION OF THE FINDINGS & FURTHER RECOMMENDATIONS

The CT study presents without abnormalities, explaining the described nasal discharge. There are no signs for active rhinitis or nasal mass lesion.



PATIENT

Pandora Hamilton

SPECIES

Canine

BREED

Corgi - Pembroke
Welsh

SEX

F

AGE

7 Years, 7 Months

INTERPRETED BY

Sebastian Schaub, DVM
Dr. med. vet. DipECVDI

HOSPITAL NAME

State Avenue Vet
Clinic

REFERRING VET

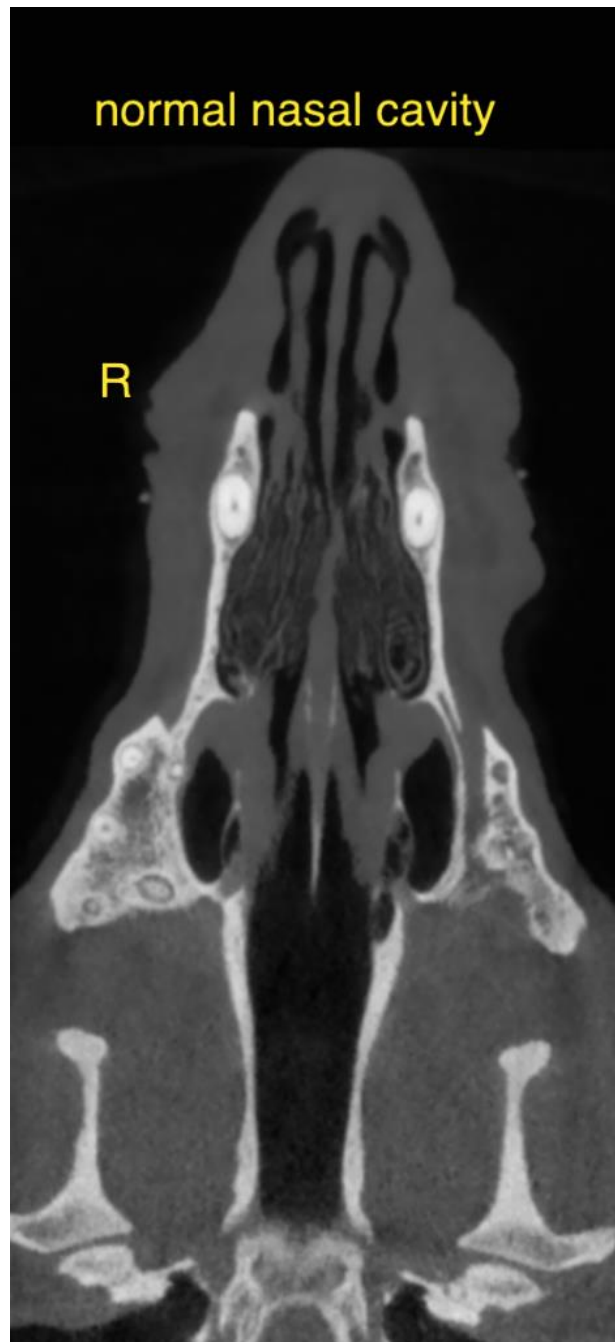
Dr. Raul Casas

INVOICE

57002

DATE

2-28-23





PATIENT

Pandora Hamilton

The information and recommendations provided are based on the images presented by the referring veterinarian/sonographer. No evaluation can be communicated regarding pathology that was not visible in the image/video clips provided.

SPECIES

Canine

Thank you for this referral. If the clinical or image interpretation does not parallel your findings or if I can be of any further assistance please contact me.

BREED

Corgi – Pembroke
Welsh

Sebastian Schaub, Sebastian Schaub, DVM, Dr. med. vet. DipECVDI
sebast.schaub@gmail.com

SEX

F

AGE

7 Years, 7 Months

INTERPRETED BY

Sebastian Schaub, DVM
Dr. med. vet. DipECVDI

HOSPITAL NAME

State Avenue Vet
Clinic

REFERRING VET

Dr. Raul Casas

INVOICE

57002

DATE

2-28-23