



PATIENT PRESENTING CLINICAL SIGNS

Perrito Benincasa Acute onset of pelvic limb paresis
Abnormal PE/Chem/CBC/UA Results: Down in rear

SPECIES COMPUTED TOMOGRAPHY OF THE THORACIC & LUMBAR SPINE

Canine A high resolution pre- and post-contrast CT study of the thoracic & lumbar spine is provided for review.

COMPUTED TOMOGRAPHIC FINDINGS

BREED

THE LAST RIB BEARING VERTEBRA IS COUNTED AS T13.

SEX

Vizsla Multifocal moderate spondylosis formation is seen along the thoracic & lumbar spine.

AGE

Multifocal mild peripheral mineralization of the dural tube is appreciated.

INTERPRETED BY

Neutered Male A vacuum phenomenon is seen in the intervertebral disc space L5/L6 – with gas dissecting up into the subchondral bone of the caudal vertebral endplate of L5.

Sebastian Schaub, DVM
Dr. med. vet. DipECVDI

AGE

10.4 Years The periarticular bones of the left shoulder joint present moderate osteophyte new bone formation. Both coxofemoral joints present moderate osteophyte new bone formation.

In the left lateral liver lobe and possibly the quadrate liver lobe, heterogeneous contrast enhancing nodules are visible respectively; measuring up to 2.8 cm in diameter.

The remainder of the osseous and soft tissue structures of the thoracic & lumbar spine are within normal limits.

INTERPRETED BY

COMPUTED TOMOGRAPHIC DIAGNOSIS

HOSPITAL NAME

- Discopathy L5/L6 without signs of compressive myelopathy
- Spondylosis deformans
- Hepatic parenchymal nodules, left lateral liver lobe and possibly quadrate liver lobe
- Degenerative osteoarthritis coxofemoral joints bilaterally
- Degenerative osteoarthritis left shoulder joint
- No evidence of degenerative lumbosacral stenosis

Mobile Pet Imaging

REFERRING VET

Meaux

INTERPRETATION OF THE FINDINGS & FURTHER RECOMMENDATIONS

INVOICE

50592

The current CT study of the thoracic & lumbar spine presents without macromorphological abnormalities, explaining the acute onset of paraparesis. Given the acuter clinical onset of clinical signs, either ischemic myelopathy (e.g. fibrocartilaginous embolism) or acute non-compressive nucleus pulposus extrusion are considerations here. If there is strong clinical suspicion for compressive myelopathy, complementing workup by a myelographic CT study or MRI study of the spine may be beneficial.

DATE

2-28-22

After rehabilitation phase, recommend workup of the hepatic intraparenchymal nodules – differentials include primary hepatic neoplasia (e.g. hepatocellular adenoma/carcinoma), regeneration nodule/nodular hyperplasia, granuloma.



PATIENT

Perrito Benincasa

SPECIES

Canine

BREED

Vizsla

SEX

Neutered Male

AGE

10.4 Years

INTERPRETED BY

Sebastian Schaub, DVM
Dr. med. vet. DipECVDI

HOSPITAL NAME

Mobile Pet Imaging

REFERRING VET

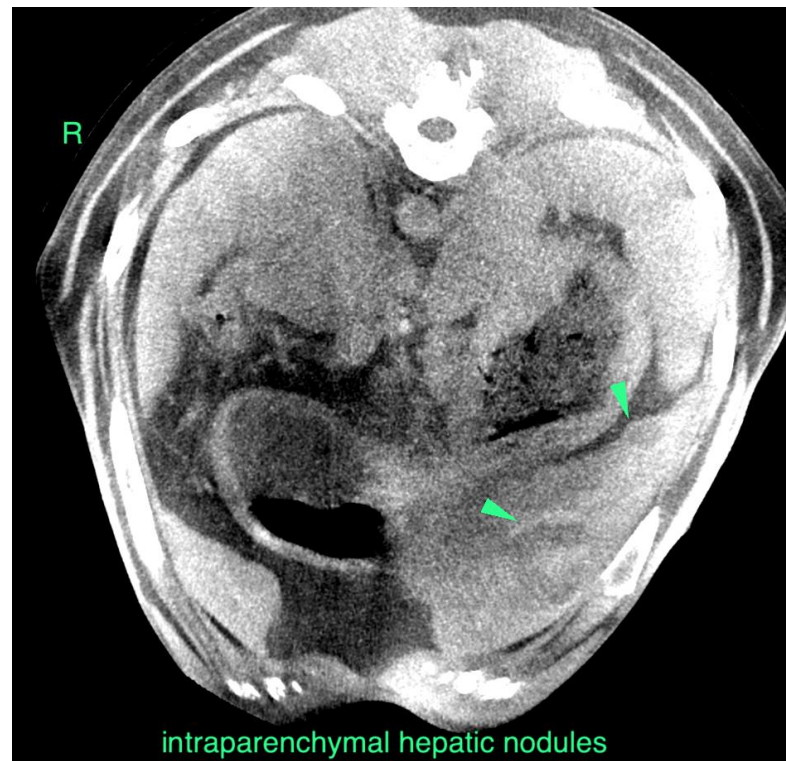
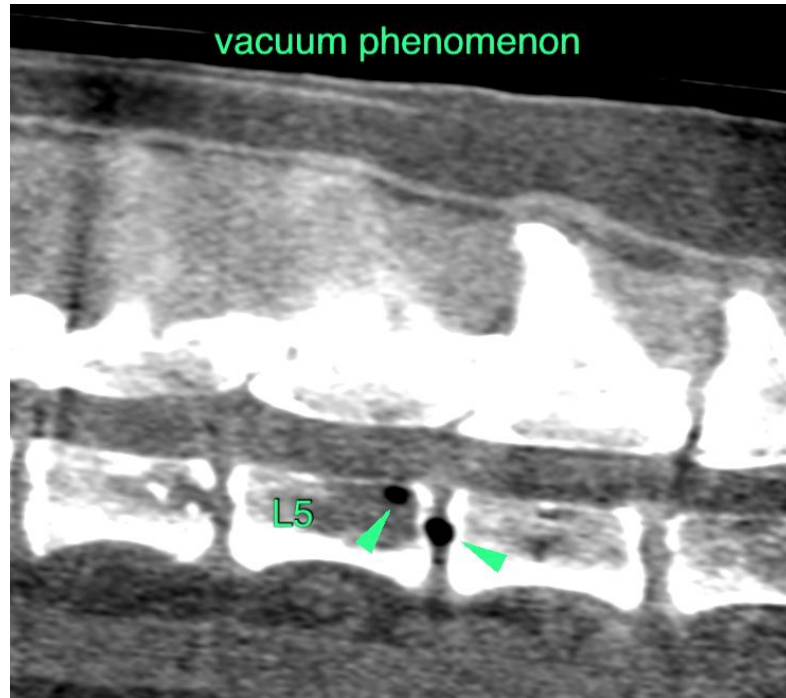
Meaux

INVOICE

50592

DATE

2-28-22





PATIENT

Perrito Benincasa

SPECIES

Canine

The information and recommendations provided are based on the images presented by the referring veterinarian/sonographer. No evaluation can be communicated regarding pathology that was not visible in the image/video clips provided.

BREED

Vizsla

Thank you for this referral. If the clinical or image interpretation does not parallel your findings or if I can be of any further assistance please contact me.

Sebastian Schaub, Sebastian Schaub, DVM, Dr. med. vet. DipECVDI
sebast.schaub@gmail.com

SEX

Neutered Male

AGE

10.4 Years

INTERPRETED BY

Sebastian Schaub, DVM
Dr. med. vet. DipECVDI

HOSPITAL NAME

Mobile Pet Imaging

REFERRING VET

Meaux

INVOICE

50592

DATE

2-28-22