



PATIENT

Thor Riesgo

SPECIES

Canine

BREED

Beagle

SEX

Neutered Male

AGE

10

WEIGHT

62

INTERPRETED BY

Sebastian Schaub, DVM
Dr. med. vet. DipECVDI

IMAGING PERFORMED BY

Armando Sobrado

HOSPITAL NAME

Miami Springs AH

REFERRING VET

Dr. Andres Perez

INVOICE

36018

DATE

2/27/26

PRESENTING CLINICAL SIGNS

- Thor presents for a re-evaluation of his seizure activity. He was started on Phenobarbital 64.8 mg twice daily 15 days ago, with the last dose administered this morning.

COMPUTED TOMOGRAPHIC STUDY OF THE SKULL

A high resolution pre- and post-contrast CT study of the skull is provided for review.

COMPUTED TOMOGRAPHIC FINDINGS

Triadan 308 is absent.

The nasal cavity presents the expected aerated spaces between thin & even conchae and turbinates with smooth mucosal lining.

Both temporomandibular joints present congruent joint spaces with even subchondral bone surfaces and are considered within normal limits.

Both tympanic bullae are aerated, the mucosal lining is not seen, the bony wall is smooth and thin. The external ear canals are within normal limits.

The brain presents no deviation from normal anatomy and symmetry. The brain parenchyma is homogeneous and within normal limits for attenuation and distribution of contrast enhancement. The ventricular system is non-dilated and symmetric.

The submandibular and medial retropharyngeal lymph nodes are small and elongated with a normal short-to-long-axis-ratio is < 0.5, the attenuation and contrast enhancement pattern is uniform.

COMPUTED TOMOGRAPHIC DIAGNOSIS

- Absent triadan 308
- Normal brain

INTERPRETATION OF THE FINDINGS & FURTHER RECOMMENDATIONS

In the present study of the brain there is no evidence of macromorphological disease, which supports the presumptive diagnosis of idiopathic epilepsy.

If not yet done so the workup should be complemented by examination of CSF and complete bloodwork to screen for brain disease that is not necessarily associated with structural changes of the brain parenchyma and rule out hepatoencephalopathy and other systemic illness. In case of the strong clinical suspicion of structural intraparenchymal changes an MRI may be considered.



PATIENT

Thor Riesgo

SPECIES

Canine

BREED

Beagle

SEX

Neutered Male

AGE

10

WEIGHT

62

INTERPRETED BY

Sebastian Schaub, DVM
Dr. med. vet. DipECVDI

IMAGING PERFORMED BY

Armando Sobrado

HOSPITAL NAME

Miami Springs AH

REFERRING VET

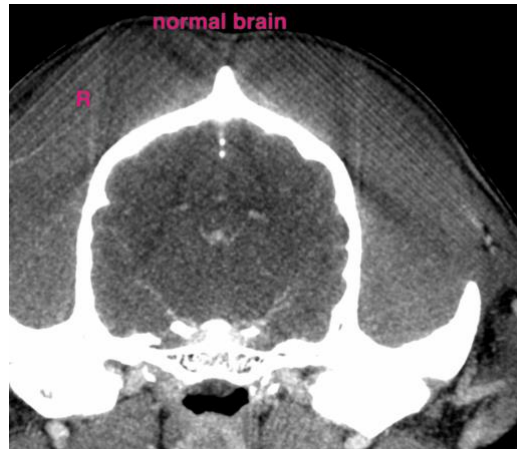
Dr. Andres Perez

INVOICE

36018

DATE

2/27/26



The information and recommendations provided are based on the images presented by the referring veterinarian/sonographer. No evaluation can be communicated regarding pathology that was not visible in the image/video clips provided.

Thank you for this referral. If the clinical or image interpretation does not parallel your findings or if I can be of any further assistance please contact me.

Sebastian Schaub, DVM, Dr. med. vet. DipECVDI
info@sonopath.com