

PATIENT

Lola Solomon

SPECIES

Canine

BREED

Frenchie

SEX

Spayed Female

AGE

11 Years

WEIGHT

25 Pounds

INTERPRETED BY

Sebastian Schaub, DVM
Dr. med. vet. DipECVCI

IMAGING PERFORMED BY

Dr. Marcela Salas

HOSPITAL NAME

Tenaflly VC

REFERRING VET

Dr. Marcela Salas

INVOICE

36019

DATE

2/27/26

PRESENTING CLINICAL SIGNS

- History for Lola solomon- rads and CT (same):
- [10:09 AM]11 yr old 25 lb FS French Bulldog: presented on 2/10 for OS red eye, bulbophthalmic with normal tonometry pressures. Sent home with Clavamox and Pred and full labs wnl. Pet seemed asymptomatic otherwise. Recheck exam 2 weeks later, eye still red but less swollen and frontal/brow ridge is irregular and firm and hypertrophied. Pet is still asymptomatic. Skull rads and CT show osteolysis. Rads and CT submitted.

COMPUTED TOMOGRAPHIC STUDY OF THE SKULL

A high resolution pre- and post-contrast CT study of the neurocranium is provided for review.

COMPUTED TOMOGRAPHIC FINDINGS

Only the dorsal aspects of the calvarium are included in the field of view.

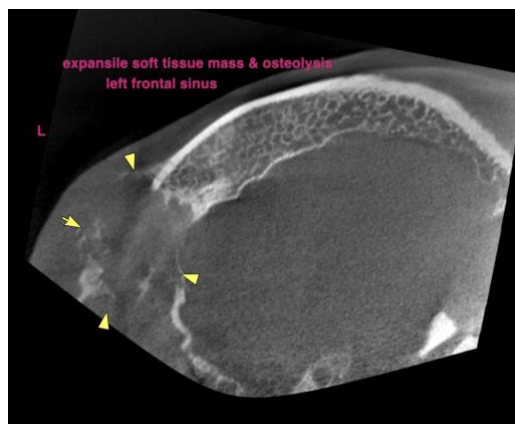
The left frontal sinus is obliterated by soft tissue attenuating material, perforating the dorsal osseous lining, causing outward deviation of the osseous lining. The left frontal bone presents permeative osteolysis along with immature periosteal new bone formation dorsally. The cranial fossa is perforated.

COMPUTED TOMOGRAPHIC DIAGNOSIS

- Aggressive predominant expansile osteolytic lesion left frontal bone with perforation of the cranial fossa
- Soft tissue material in left frontal sinus

INTERPRETATION OF THE FINDINGS & FURTHER RECOMMENDATIONS

The findings of the left frontal sinus and frontal bone are most consistent with primary soft tissue neoplasia originating from the left frontal sinus – adenocarcinoma is most likely. A differential is primary osseous neoplasm, such as osteosarcoma, chondrosarcoma, fibrosarcoma. FNA sampling/biopsy of the subcutaneous swelling can be performed for specification.



The information and recommendations provided are based on the images presented by the referring veterinarian/sonographer. No evaluation can be communicated regarding pathology



PATIENT

Lola Solomon

SPECIES

Canine

BREED

Frenchie

SEX

Spayed Female

AGE

11 Years

WEIGHT

25 Pounds

INTERPRETED BY

Sebastian Schaub, DVM
Dr. med. vet. DipECVDI

**IMAGING
PERFORMED BY**

Dr. Marcela Salas

HOSPITAL NAME

Tenaflly VC

REFERRING VET

Dr. Marcela Salas

INVOICE

36019

DATE

2/27/26

that was not visible in the image/video clips provided.

Thank you for this referral. If the clinical or image interpretation does not parallel your findings or if I can be of any further assistance please contact me.

Sebastian Schaub, DVM, Dr. med. vet. DipECVDI

info@sonopath.com