



## PATIENT

James Marks

## SPECIES

Feline

## BREED

DSH

## SEX

Neutered Male

## AGE

5 Years 5 Months

## WEIGHT

4.10 kg

## INTERPRETED BY

Sebastian Schaub, DVM  
Dr. med. vet. DipECVDI

## IMAGING PERFORMED BY

Lucy

## HOSPITAL NAME

Bridgwater VH & WC

## REFERRING VET

Dr. Jennifer Vander Koi

## INVOICE

36020

## DATE

2/27/26

## PRESENTING CLINICAL SIGNS

History of Otitis since kitten. Polyp type mass identified in 2022 but unable to reach and remove. Ongoing intermittent otitis referring for CT prior to either a TECA or Ventra Bulla Osteotomy as requested by Great Plains Veterinary Surgery.

## COMPUTED TOMOGRAPHIC STUDY OF THE SKULL

A high resolution pre- and post-contrast CT study of the skull is provided for review.

## COMPUTED TOMOGRAPHIC FINDINGS

All teeth but triadan 104, 107, 109, 204, 304, 404, 407 and 408 are absent.

The nasal cavity presents the expected aerated spaces between thin & even conchae and turbinates with smooth mucosal lining.

Both temporomandibular joints present congruent joint spaces with even subchondral bone surfaces and are considered within normal limits.

Both tympanic bullae obliterated by non-contrast enhancing soft tissue material. The osseous lining of the right tympanic bulla is severely irregularly thickened and presents moth eaten defects. The horizontal segment of the right external ear canal is obliterated by expansile soft tissue material, perforating the wall of the external ear canal. The mass of the right external ear canal is protruding into the soft tissues lateral to the right tympanic bulla – presenting peripherally accentuated contrast enhancement.

The osseous labyrinth of the right inner ear presents moderate irregular hyperostosis and moth eaten osteolytic lesions.

The brain presents no deviation from normal anatomy and symmetry. The brain parenchyma is homogeneous and within normal limits for attenuation and distribution of contrast enhancement. The ventricular system is non-dilated and symmetric.

The medial retropharyngeal lymph node bilaterally and the right lateral retropharyngeal lymph node are moderately prominent and have a heterogeneous contrast enhancement pattern.

## COMPUTED TOMOGRAPHIC DIAGNOSIS

- Soft tissue mass medial aspect right external ear canal and right tympanic bulla
- Perforated right external ear canal with thick walled cavitory lesion lateral to the right tympanic bulla
- Right sided chronic otitis media and interna with osseous remodeling of the osseous lining
- Lymphadenopathy medial retropharyngeal lymph nodes and right lateral retropharyngeal lymph node
- Multiple absent teeth with secondary atrophy of the alveolar bone in all jaw quadrants

## INTERPRETATION OF THE FINDINGS & FURTHER RECOMMENDATIONS

The changes of the right external, middle and inner ear are most suggestive for chronic otitis externa, media and interna. Chronic inflammation has likely resulted in inflammatory polyp formation and caused perforation of the right external ear canal with secondary abscess formation. A differential is



## PATIENT

James Marks

## SPECIES

Feline

## BREED

DSH

## SEX

Neutered Male

## AGE

5 Years 5 Months

## WEIGHT

4.10 kg

## INTERPRETED BY

Sebastian Schaub, DVM  
Dr. med. vet. DipECVDI

## IMAGING PERFORMED BY

Lucy

## HOSPITAL NAME

Bridgwater VH & WC

## REFERRING VET

Dr. Jennifer Vander Koi

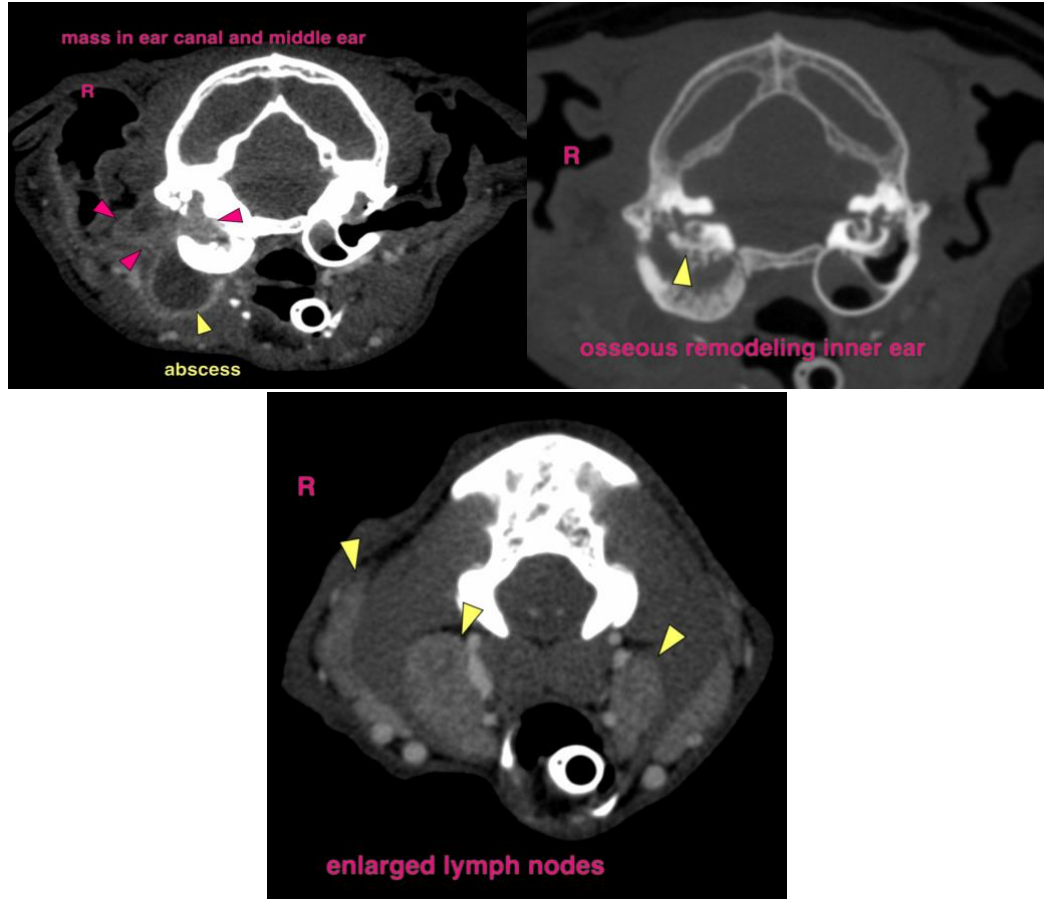
## INVOICE

36020

## DATE

2/27/26

primary soft tissue neoplasia of the right external ear canal – such as ceruminous gland adenocarcinoma or squamous cell carcinoma – although I consider the odds lower. Anyway, prior to surgical management, biopsy of the mass in the ear canal is strongly recommended for differentiation between benign inflammatory polyp versus malignant neoplasia.



The information and recommendations provided are based on the images presented by the referring veterinarian/sonographer. No evaluation can be communicated regarding pathology that was not visible in the image/video clips provided.

Thank you for this referral. If the clinical or image interpretation does not parallel your findings or if I can be of any further assistance please contact me.

Sebastian Schaub, DVM, Dr. med. vet. DipECVDI  
[info@sonopath.com](mailto:info@sonopath.com)