



PATIENT

Holly Shipee

SPECIES

Feline

BREED

DLH

SEX

Spayed Female

AGE

4 Years

WEIGHT

8.8 Pounds

INTERPRETED BY

Sebastian Schaub, DVM
Dr. med. vet. DipECVDI

IMAGING PERFORMED BY

Alyssa

HOSPITAL NAME

Queen Creek VC

REFERRING VET

Dr. Kelsey Sampayan

INVOICE

36024

DATE

2/27/26

PRESENTING CLINICAL SIGNS

- P is acting like something in her mouth - meowing a lot and following O around like something is wrong. O states P has been moving stuff around / doing weird mouth movement like something in there.
- Odd mouth movement- R/O jaw pain vs inner ear issue vs other

COMPUTED TOMOGRAPHIC STUDY OF THE SKULL

A high resolution pre- and post-contrast CT study of the skull is provided for review.

COMPUTED TOMOGRAPHIC FINDINGS

Triadan 204 is absent.

The nasal cavity presents the expected aerated spaces between thin & even conchae and turbinates with smooth mucosal lining.

Both temporomandibular joints present congruent joint spaces with even subchondral bone surfaces and are considered within normal limits.

Both tympanic bullae are aerated, the mucosal lining is not seen, the bony wall is smooth and thin. The external ear canals are within normal limits.

The brain presents no deviation from normal anatomy and symmetry. The brain parenchyma is homogeneous and within normal limits for attenuation and distribution of contrast enhancement. The ventricular system is non-dilated and symmetric.

The submandibular and medial retropharyngeal lymph nodes are small and elongated with a normal short-to-long-axis-ratio is < 0.5, the attenuation and contrast enhancement pattern is uniform.

COMPUTED TOMOGRAPHIC DIAGNOSIS

- Absent triadan 204
- No evidence of otitis media

INTERPRETATION OF THE FINDINGS & FURTHER RECOMMENDATIONS

The CT study reveals no clinically relevant abnormalities and an underlying cause for the presenting clinical signs cannot be specified.



PATIENT

Holly Shippee

SPECIES

Feline

BREED

DLH

SEX

Spayed Female

AGE

4 Years

WEIGHT

8.8 Pounds

INTERPRETED BY

Sebastian Schaub, DVM
Dr. med. vet. DipECVDI

IMAGING PERFORMED BY

Alyssa

HOSPITAL NAME

Queen Creek VC

REFERRING VET

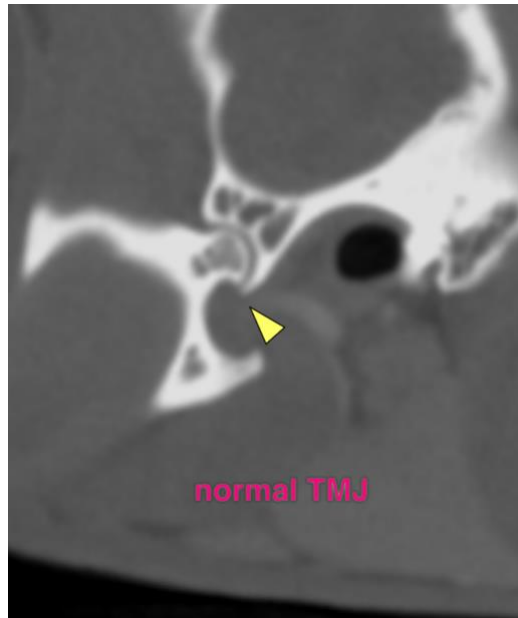
Dr. Kelsey Sampayan

INVOICE

36024

DATE

2/27/26



The information and recommendations provided are based on the images presented by the referring veterinarian/sonographer. No evaluation can be communicated regarding pathology that was not visible in the image/video clips provided.

Thank you for this referral. If the clinical or image interpretation does not parallel your findings or if I can be of any further assistance please contact me.

Sebastian Schaub, DVM, Dr. med. vet. DipECVDI
info@sonopath.com