



PATIENT

Bailey Bier

SPECIES

Canine

BREED

Goldendoodle

SEX

Spayed Female

AGE

4

WEIGHT

32

INTERPRETED BY

Sebastian Schaub, DVM
Dr. med. vet. DipECVDI

IMAGING PERFORMED BY

Armando Sobrado

HOSPITAL NAME

Miami Springs AH

REFERRING VET

Dr. Andres Perez

INVOICE

36022

DATE

2/27/26

PRESENTING CLINICAL SIGNS

PET HAS HEAD TILD TO THE LEFT WITH NYSTAGMUS TO THE FAST FASE TO THE RIGHT.

COMPUTED TOMOGRAPHIC STUDY OF THE SKULL

A high resolution pre- and post-contrast CT study of the skull is provided for review.

COMPUTED TOMOGRAPHIC FINDINGS

A supernumerary triadan 311 and 411 is appreciated.

Mild consolidation of the nasal cavity bilaterally is appreciated.

Both temporomandibular joints present congruent joint spaces with even subchondral bone surfaces and are considered within normal limits.

The left tympanic bulla is partially obliterated by gravity dependent, soft tissue attenuating material. The osseous lining of the left tympanic bulla is mildly thickened and smooth. Gas is appreciated in the cochlea of the left inner ear. The external ear canals are within normal limits.

The brain presents no deviation from normal anatomy and symmetry. The brain parenchyma is homogeneous and within normal limits for attenuation and distribution of contrast enhancement. The ventricular system is non-dilated and symmetric.

The submandibular and medial retropharyngeal lymph nodes are small and elongated with a normal short-to-long-axis-ratio is < 0.5, the attenuation and contrast enhancement pattern is uniform.

COMPUTED TOMOGRAPHIC DIAGNOSIS

- Left sided otitis media and interna
- Supernumerary triadan 311 and 411

INTERPRETATION OF THE FINDINGS & FURTHER RECOMMENDATIONS

The left sided otitis media and secondary otitis interna is a plausible explanation for the presenting vestibular clinical signs. Myringotomy can be used as minimally invasive diagnostic tool for sampling and flushing the left tympanic bulla, surgical management options can be considered alternatively.



PATIENT

Bailey Bier

SPECIES

Canine

BREED

Goldendoodle

SEX

Spayed Female

AGE

4

WEIGHT

32

INTERPRETED BY

Sebastian Schaub, DVM
Dr. med. vet. DipECVDI

IMAGING PERFORMED BY

Armando Sobrado

HOSPITAL NAME

Miami Springs AH

REFERRING VET

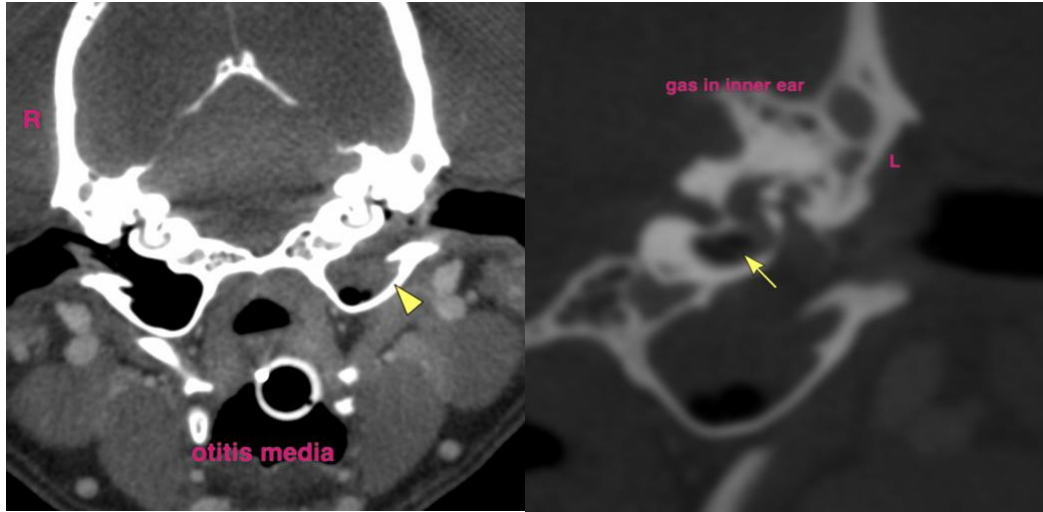
Dr. Andres Perez

INVOICE

36022

DATE

2/27/26



The information and recommendations provided are based on the images presented by the referring veterinarian/sonographer. No evaluation can be communicated regarding pathology that was not visible in the image/video clips provided.

Thank you for this referral. If the clinical or image interpretation does not parallel your findings or if I can be of any further assistance please contact me.

Sebastian Schaub, DVM, Dr. med. vet. DipECVDI
info@sonopath.com