

**PATIENT**Groucho Barx  
Hansmeier**PRESENTING CLINICAL SIGNS**

Lisa thinks she may need R TPLO done. Toe touching off and on. Came in for wellness on 2-4-23.  
Xrays taken 2-24-23.

Abnormal PE/Chem/CBC/UA Results: TPLO on L stifle with resultant inflammation and enlargement of joint. R stifle enlarged and painful due to chronic partial and now complete tear of CCL. R hindlimb intermittently toe-touching.

**SPECIES**

Canine

**RADIOGRAPHIC STUDY OF THE PELVIS AND RIGHT STILFE JOINT**

Ventrodorsal projection of the pelvis and radiographs of the right stifle joint in two orthogonal imaging planes are provided for review.

**BREED**

Old English Bulldog

**RADIOGRAPHIC FINDINGS**

The periarticular bones of both stifle joints present moderate osteophyte new bone formation. The coxofemoral joints space is incongruent, L>R. The center of the femoral heads is level with/lateral to the dorsal acetabular rim.

**SEX**

Spayed

The periarticular bones of the right stifle joint present moderate osteophyte new bone formation. A moderate intracapsular soft tissue swelling of the right stifle joint is seen. Mild cranial subluxation of the tibial plateau is seen.

**AGE**

7 Years, 1 Month

The included parts of the left stifle joint in the craniocaudal projection present moderate osteophyte new bone formation of the periarticular bones.

**INTERPRETED BY**Sebastian Schaub, DVM  
Dr. med. vet. DipECVDI

- Moderate degenerative osteoarthritis stifle joints bilaterally
- Moderate articular swelling right stifle joint
- Right sided mild cranial tibial subluxation
- Degenerative osteoarthritis coxofemoral joints bilaterally, due to hip dysplasia

**HOSPITAL NAME**Elizabeth Animal  
Hospital**INTERPRETATION OF THE FINDINGS & FURTHER RECOMMENDATIONS**

The degenerative joint disease with joint effusion of the right stifle joint is a sequela to failure of the cranial cruciate ligament ± meniscal disease.

**REFERRING VET**

Leon Anderson, DVM

**INVOICE**

56959

**DATE**

2-27-23



**PATIENT**

Groucho Barx  
Hansmeier

**SPECIES**

Canine

**BREED**

Old English Bulldog

**SEX**

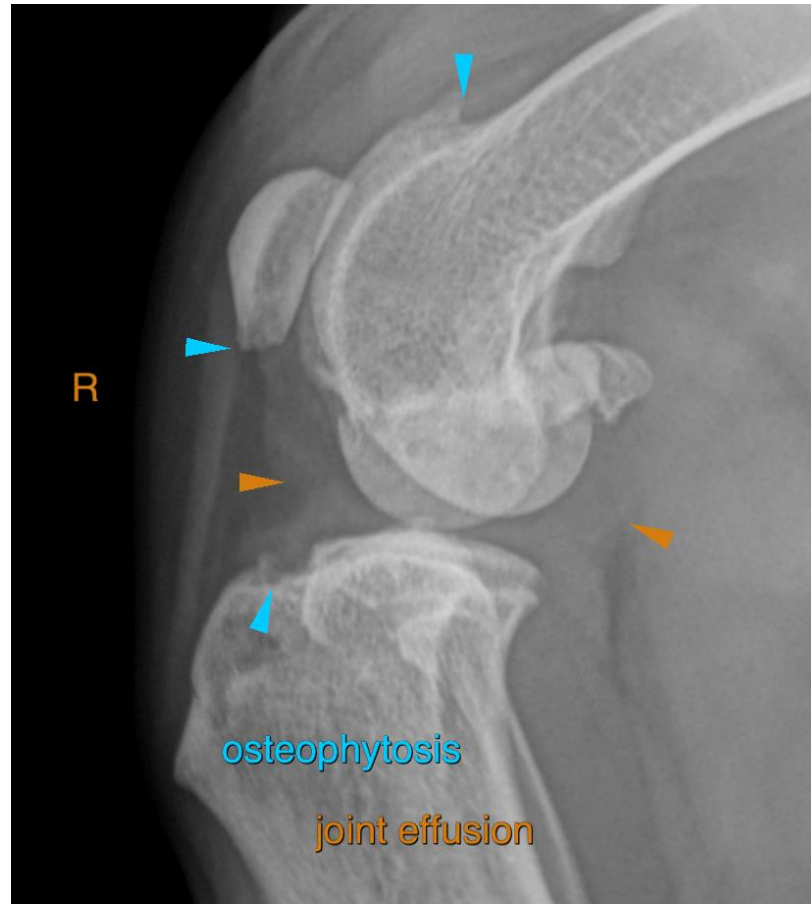
Spayed

**AGE**

7 Years, 1 Month

**INTERPRETED BY**

Sebastian Schaub, DVM  
Dr. med. vet. DipECVDI



**HOSPITAL NAME**

Elizabeth Animal  
Hospital

**REFERRING VET**

Leon Anderson, DVM

**INVOICE**

56959

**DATE**

2-27-23

The information and recommendations provided are based on the images presented by the referring veterinarian/sonographer. No evaluation can be communicated regarding pathology that was not visible in the image/video clips provided.

Thank you for this referral. If the clinical or image interpretation does not parallel your findings or if I can be of any further assistance please contact me.

**Sebastian Schaub**, Sebastian Schaub, DVM, Dr. med. vet. DipECVDI  
sebast.schaub@gmail.com