



**PATIENT PRESENTING CLINICAL SIGNS**

Elton Chen History of left sided head tilt and otitis externa. Otitis resolved however patient intermittently yelps in pain, intermittently has a left sided head tilt as well. Left ear drum ruptured detected in December.

**SPECIES COMPUTED TOMOGRAPHY OF THE SKULL**

Canine A pre- and post-contrast CT study of the skull in a bone and soft tissue reconstruction is provided for review.

**BREED COMPUTED TOMOGRAPHIC FINDINGS**

Shiba Inu Triadan 311 is absent.

The nasal cavity presents the expected aerated spaces between thin & even conchae and turbinates with smooth mucosal lining.

**SEX**

MN

Both temporomandibular joints present congruent joint spaces with even subchondral bone surfaces and are considered within normal limits.

**AGE**

8 Years

The left tympanic bulla is filled with fluid attenuating material, the osseous wall is mildly irregular. The left tympanic bulla is aerated, the mucosal lining is not seen, the bony wall is smooth and thin. In the left external ear canal, a small amount of soft tissue material is attached to the epithelial lining.

**INTERPRETED BY**

Sebastian Schaub, DVM  
Dr. med. vet. DipECVDI

The brain presents no deviation from normal anatomy and symmetry. The brain parenchyma is homogeneous and within normal limits for attenuation and distribution of contrast enhancement. The ventricular system is non-dilated and symmetric.

The submandibular and medial retropharyngeal lymph nodes are small and elongated with a normal short-to-long-axis-ratio is < 0.5, the attenuation and contrast enhancement pattern is uniform.

**HOSPITAL NAME**

Colyton Veterinary  
Hospital

**COMPUTED TOMOGRAPHIC DIAGNOSIS**

- History of left sided otitis externa
- Left sided otitis media
- Absent triadan 311

**REFERRING VET**

Dalton Nguyen

**INTERPRETATION OF THE FINDINGS & FURTHER RECOMMENDATIONS**

The left sided otitis media might trigger left sided otitis interna as possible source for the intermittent head tilt. No additional clinically relevant abnormalities are appreciated.

**INVOICE**

56942

**DATE**

2-27-23



**PATIENT**

Elton Chen

**SPECIES**

Canine

**BREED**

Shiba Inu

**SEX**

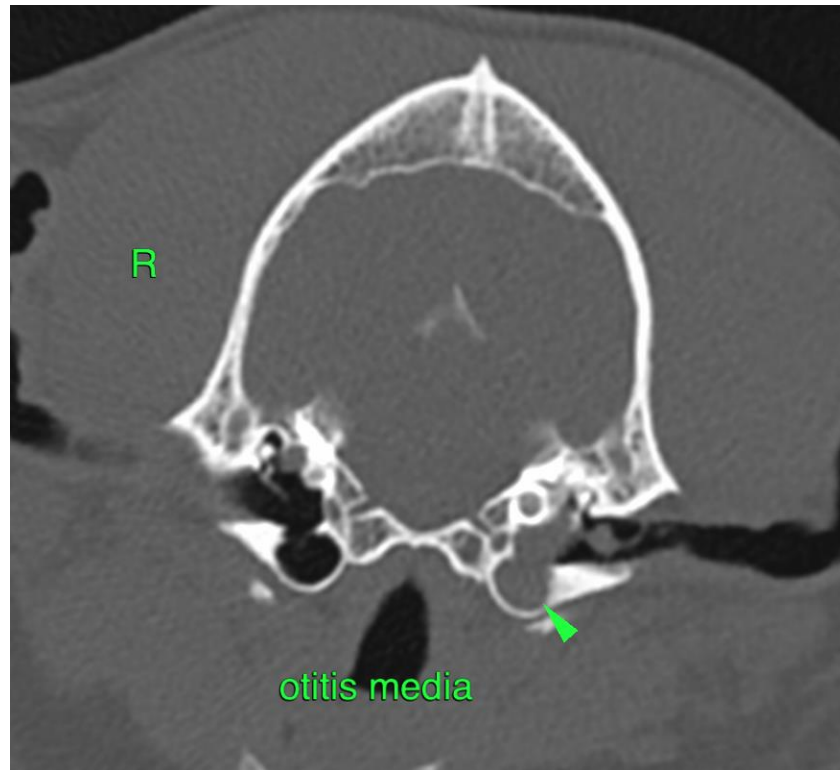
MN

**AGE**

8 Years

**INTERPRETED BY**

Sebastian Schaub, DVM  
Dr. med. vet. DipECVDI



**HOSPITAL NAME**

Colyton Veterinary  
Hospital

**REFERRING VET**

Dalton Nguyen

**INVOICE**

56942

**DATE**

2-27-23

The information and recommendations provided are based on the images presented by the referring veterinarian/sonographer. No evaluation can be communicated regarding pathology that was not visible in the image/video clips provided.

Thank you for this referral. If the clinical or image interpretation does not parallel your findings or if I can be of any further assistance please contact me.

**Sebastian Schaub**, Sebastian Schaub, DVM, Dr. med. vet. DipECVDI  
sebast.schaub@gmail.com