



PATIENT PRESENTING CLINICAL SIGNS

Bella Santos cat not eating for the past couple of days. Last BW done a few months ago, with no concerns. Vomited 1x today as per Owner. Need to r/o FB vs neoplasia vs others

SPECIES RADIOGRAPHIC STUDY OF THE ABDOMEN

Feline Radiographs of the abdomen in three imaging planes are provided for review.

RADIOGRAPHIC FINDINGS

BREED The intervertebral disc spaces T13/L1 and L1/L2 are collapsed and the respective vertebral endplates present mild spondylosis formation.

DSH No abnormalities of the extraabdominal soft tissues are noted. The abdominal wall is smooth and thin.

SEX The serosal detail is maintained throughout the peritoneal and retroperitoneal space.

Female The liver is appropriate in position, size and presents uniform opacity.

The splenic head is in the anticipated position and within normal limits for size and opacity.

AGE Both kidneys are seen and present with normal size, shape, delineation. Small mineralization are seen in the imaging plane of the renal pelvis bilaterally. A small The urinary bladder is in its anticipated position. No radiopaque calculi are noted throughout the lower urinary tract.

12 Years

INTERPRETED BY The stomach is in its anticipated position and presents normal content.

Sebastian Schaub, DVM
Dr. med. vet. DipECVDI

The small intestinal loops are of even diameter and non-dilated, a small amount of gas is seen within the small intestinal loops and considered within normal limits.

The colon is seen in the expected position and presents with appropriate content.

HOSPITAL NAME RADIOGRAPHIC DIAGNOSIS

Truscott Animal Hospital

- Nephrolithiasis
- Chronic discopathy T13/L1 and L1/L2

REFERRING VET INTERPRETATION OF THE FINDINGS & FURTHER RECOMMENDATIONS

Dr. Medhat Meawad

The radiographic study of the abdomen presents no specific clinically relevant abnormalities. There is no evidence of radiopaque foreign material, abnormal gas pattern or signs for gastrointestinal mechanical obstruction. No abdominal mass is appreciated. If not done so yet, recommend complementing workup by complete blood work.

INVOICE

56970

DATE

2-27-23



PATIENT

Bella Santos

SPECIES

Feline

BREED

DSH

SEX

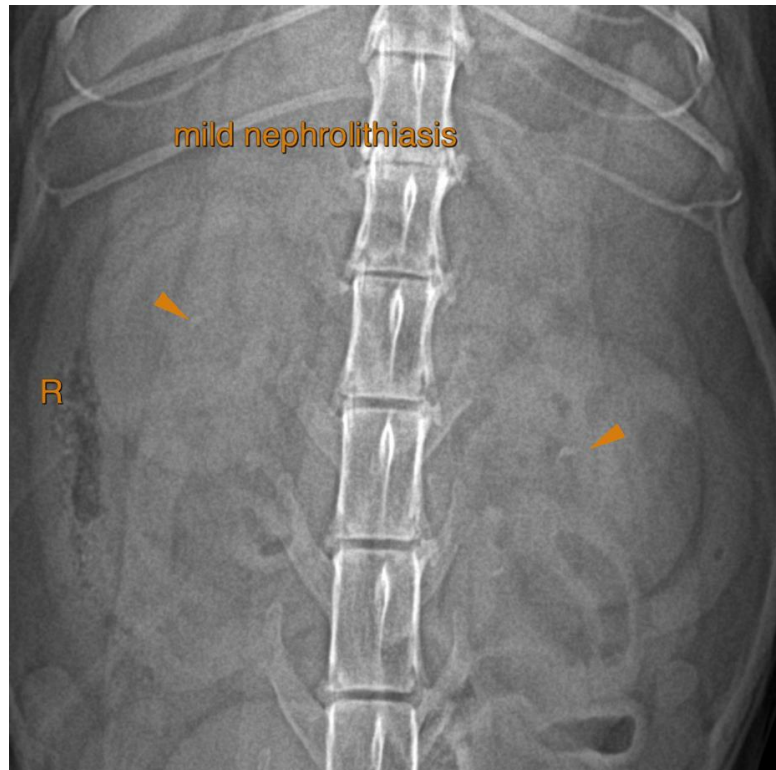
Female

AGE

12 Years

INTERPRETED BY

Sebastian Schaub, DVM
Dr. med. vet. DipECVDI



HOSPITAL NAME

Truscott Animal
Hospital

REFERRING VET

Dr. Medhat Meawad

INVOICE

56970

DATE

2-27-23

The information and recommendations provided are based on the images presented by the referring veterinarian/sonographer. No evaluation can be communicated regarding pathology that was not visible in the image/video clips provided.

Thank you for this referral. If the clinical or image interpretation does not parallel your findings or if I can be of any further assistance please contact me.

Sebastian Schaub, Sebastian Schaub, DVM, Dr. med. vet. DipECVDI
sebast.schaub@gmail.com