



**PATIENT**

Baloo Bateau

**PRESENTING CLINICAL SIGNS**

Coughing for the past year. Started on Fluticasone inhaler in Oct PRN but coughing persists. Abnormal PE/Chem/CBC/UA Results: Pending.

**SPECIES**

Feline

**RADIOGRAPHIC STUDY OF THE THORAX**

Radiographs of the thorax in three imaging planes are provided for review.

**BREED**

DSH

The surrounding bony structures are within normal limits.

The extrathoracic soft tissues present homogeneous without abnormalities.

The heart is of normal size and shape, there is no evidence of cardiac chamber or vascular enlargement. The pulmonary vasculature is within normal limits.

**SEX**

Male Neutered

The trachea is normal in diameter and presents the anticipated course. The luminal outline of the trachea is smooth.

A mild increased visibility of the walls of the first and second degree bronchi is seen.

**AGE**

1 Year, 10 Months

The lung parenchyma presents the expected architecture and opacity; the intrapulmonary vascular branching is seen up to the third order lung vessels.

The diaphragm is well delineated with even surface and the expected mild cranial bulging of the diaphragmatic cupola.

**INTERPRETED BY**

Sebastian Schaub, DVM  
Dr. med. vet. DipECVDI

**RADIOGRAPHIC DIAGNOSIS**

- Very mild bronchial pattern
- No evidence of air-trapping

**HOSPITAL NAME**

Northvale Veterinary  
Clinic

**INTERPRETATION OF THE FINDINGS & FURTHER RECOMMENDATIONS**

The radiographic changes are only mild, presenting a mild bronchial pattern. In combination with the chronic history of cough, the odds for underlying feline bronchial disease ('feline asthma') are high. However, as the clinical signs persist under therapy, rule out upper airway pathologies as source for the cough as well. Lower airway sampling can be considered as advanced diagnostic tool as well.

**REFERRING VET**

Dr. Stefanie Simon

**INVOICE**

56987

**DATE**

2-27-23



**PATIENT**

Baloo Bateau

**SPECIES**

Feline

**BREED**

DSH

**SEX**

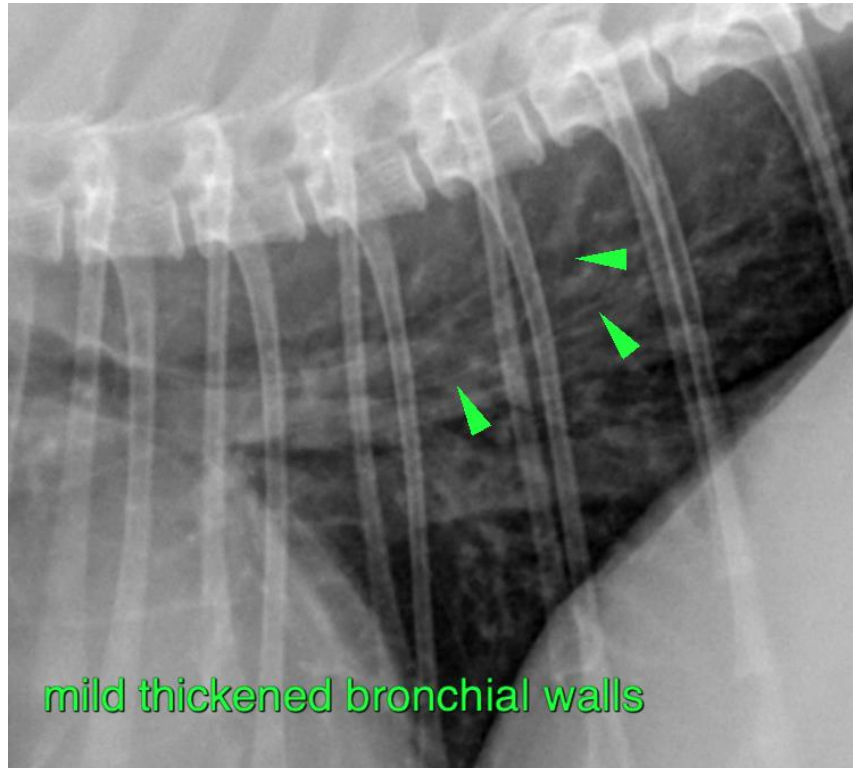
Male Neutered

**AGE**

1 Year, 10 Months

**INTERPRETED BY**

Sebastian Schaub, DVM  
Dr. med. vet. DipECVDI



**HOSPITAL NAME**

Northvale Veterinary  
Clinic

**REFERRING VET**

Dr. Stefanie Simon

**INVOICE**

56987

**DATE**

2-27-23

The information and recommendations provided are based on the images presented by the referring veterinarian/sonographer. No evaluation can be communicated regarding pathology that was not visible in the image/video clips provided.

Thank you for this referral. If the clinical or image interpretation does not parallel your findings or if I can be of any further assistance please contact me.

**Sebastian Schaub**, Sebastian Schaub, DVM, Dr. med. vet. DipECVDI  
sebast.schaub@gmail.com