

PATIENT

Avena McConnell

PRESENTING CLINICAL SIGNS

History of persistent right aortic arch surgery, coughing

SPECIES

Canine

RADIOGRAPHIC STUDY OF THE THORAX

A right lateral view of the thorax is provided for review.

BREED

German Shepard Mix

RADIOGRAPHIC FINDINGS

The surrounding bony structures are within normal limits, the growth plates are age related open.

The extrathoracic soft tissues present homogeneous without abnormalities.

The heart is of normal size and shape, there is no evidence of cardiac chamber or vascular enlargement. The pulmonary vasculature is within normal limits.

SEX

Female Intact

The intrathoracic segment of the trachea, cranial to the heart, is deviated ventrally and has an undulating course. The cranial lung lobes are mildly deviated caudally and small gas bubbles are superimposed on the cranial lung field.

AGE

20 Weeks

The bronchial tree presents with thin walls and tapers uniformly towards the periphery as expected.

The lung parenchyma presents the expected architecture and opacity; the intrapulmonary vascular branching is seen up to the third order lung vessels.

INTERPRETED BY

Sebastian Schaub, DVM
Dr. med. vet. DipECVDI

The diaphragm is well delineated with even surface and the expected mild cranial bulging of the diaphragmatic cupola.

RADIOGRAPHIC DIAGNOSIS

- History of surgical management of a vascular ring anomaly due to persistent right fourth aortic arch
- Secondary esophageal pulsation diverticulum

HOSPITAL NAME

New Bridge
Veterinary Practice

INTERPRETATION OF THE FINDINGS & FURTHER RECOMMENDATIONS

The radiographic changes are fitting the history of vascular ring anomaly and ventral tracheal deviation and foamy soft tissue material superimposed on the cranioventral lung field indicate a persistent large esophageal diverticulum. At this point I do not see evidence of aspiration pneumonia, however intermittent regurgitation with aspiration can be a source for the cough.

REFERRING VET

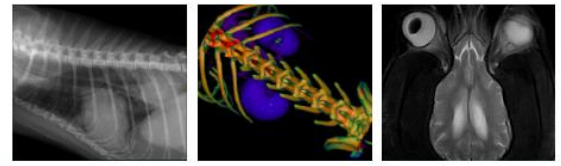
Dr. Abina Glennon

INVOICE

56946

DATE

2-27-23



PATIENT

Avena McConnell

SPECIES

Canine

BREED

German Shepard Mix

SEX

Female Intact

AGE

20 Weeks

INTERPRETED BY

Sebastian Schaub, DVM
Dr. med. vet. DipECVDI

HOSPITAL NAME

New Bridge
Veterinary Practice

REFERRING VET

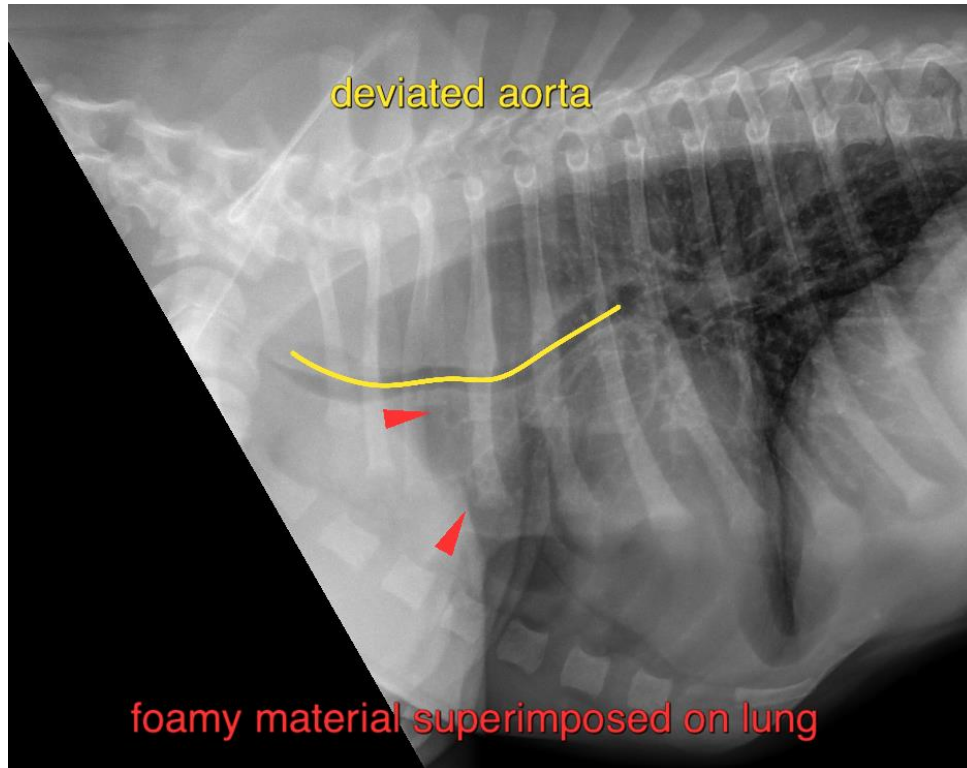
Dr. Abina Glennon

INVOICE

56946

DATE

2-27-23



The information and recommendations provided are based on the images presented by the referring veterinarian/sonographer. No evaluation can be communicated regarding pathology that was not visible in the image/video clips provided.

Thank you for this referral. If the clinical or image interpretation does not parallel your findings or if I can be of any further assistance please contact me.

Sebastian Schaub, Sebastian Schaub, DVM, Dr. med. vet. DipECVDI
sebast.schaub@gmail.com