

**PATIENT**

Ollie Belac-Crosse

PRESENTING CLINICAL SIGNS

Acute Lameness of the left front limb. Indoor/outdoor cat Has 2 scabs on the left front limb, but no abscess found. Forelimb is swollen and painful.
Abnormal PE/Chem/CBC/UA Results: mild neutrophilia Retroviruses negative

SPECIES

Feline

RADIOGRAPHIC STUDY OF THE ELBOW JOINTS

Radiographs of the left elbow joint in two orthogonal imaging planes are provided for review.

BREED

DSH

RADIOGRAPHIC FINDINGS

The left elbow joint presents smooth osseous margins. The left antebrachium presents with a circumferential, homogeneous soft tissue swelling; extending distally approximately up to the level of the left carpal joint. The osseous structures of the left antebrachium are within normal limits.

SEX

MN

RADIOGRAPHIC DIAGNOSIS

- Soft tissue swelling left antebrachium

AGE

2 Years

INTERPRETATION OF THE FINDINGS & FURTHER RECOMMENDATIONS

The soft tissue swelling of the left antebrachium is highly concerning for inflammatory origin – such as abscess, steatitis, phlegmon. Clipping the entire front limb would be beneficial to screen for bite marks. Ultrasound can be used to screen for pockets of fluid.

INTERPRETED BY

Sebastian Schaub, DVM
Dr. med. vet. DipECVDI

HOSPITAL NAME

Balmy Beach Pet
Hospital

REFERRING VET

Dr. Singh

INVOICE

50584

DATE

2-27-22



PATIENT

Ollie Belac-Crosse

SPECIES

Feline

BREED

DSH

SEX

MN

AGE

2 Years

INTERPRETED BY

Sebastian Schaub, DVM
Dr. med. vet. DipECVDI

HOSPITAL NAME

Balmy Beach Pet
Hospital

REFERRING VET

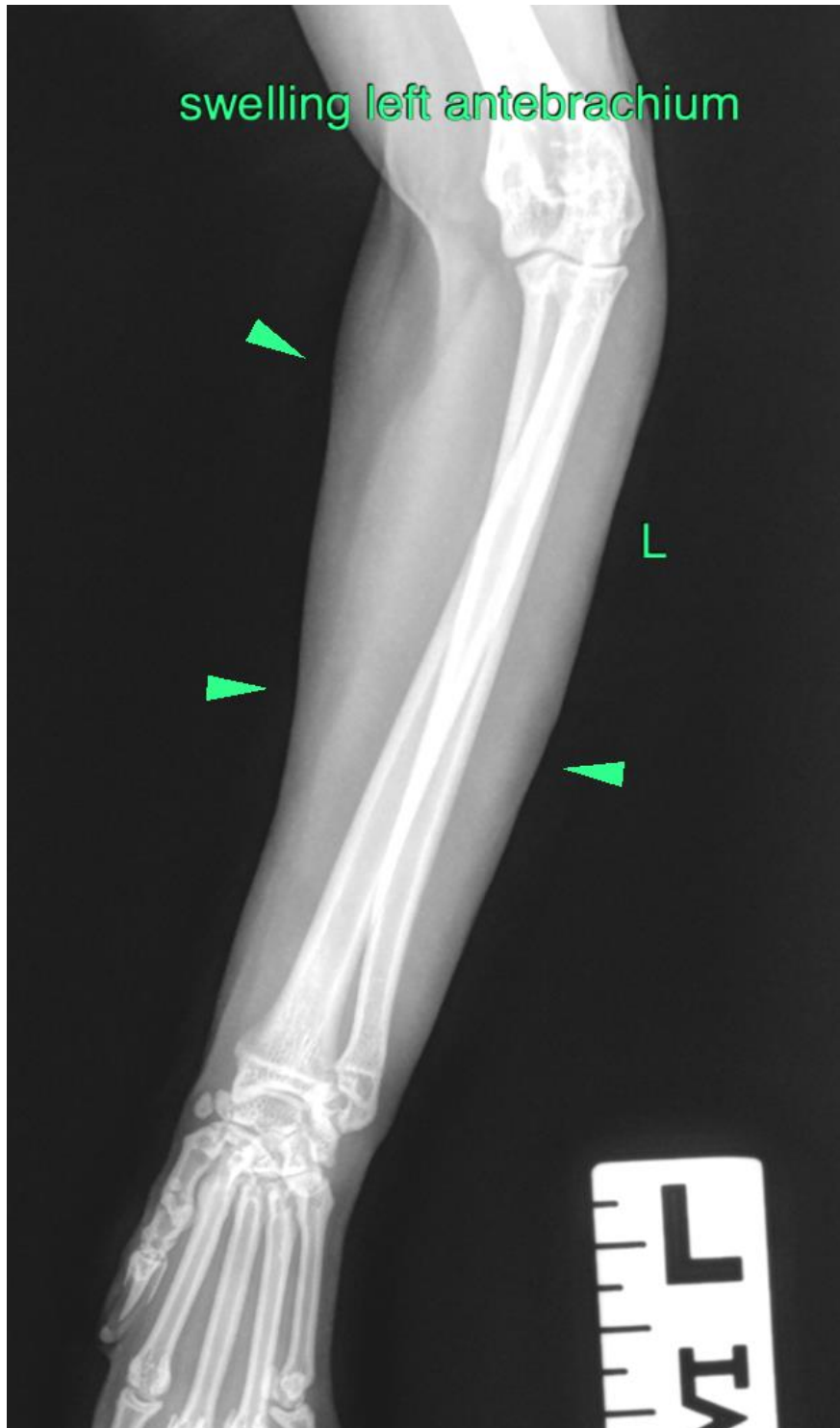
Dr. Singh

INVOICE

50584

DATE

2-27-22





PATIENT

Ollie Belac-Crosse

The information and recommendations provided are based on the images presented by the referring veterinarian/sonographer. No evaluation can be communicated regarding pathology that was not visible in the image/video clips provided.

SPECIES

Feline

Thank you for this referral. If the clinical or image interpretation does not parallel your findings or if I can be of any further assistance please contact me.

BREED

DSH

Sebastian Schaub, Sebastian Schaub, DVM, Dr. med. vet. DipECVDI
sebast.schaub@gmail.com

SEX

MN

AGE

2 Years

INTERPRETED BY

Sebastian Schaub, DVM
Dr. med. vet. DipECVDI

HOSPITAL NAME

Balmy Beach Pet
Hospital

REFERRING VET

Dr. Singh

INVOICE

50584

DATE

2-27-22