



PATIENT

Cooper Sempler

SPECIES

Canine

BREED

Cavapoo

SEX

MN

AGE

7Y, 6M

WEIGHT

28lbs

INTERPRETED BY

Sebastian Schaub, DVM
Dr. med. vet.
DipECVDI

IMAGING PERFORMED BY

Monika Salgado

HOSPITAL NAME

Westchester Animal
Hospital

REFERRING VET

Randy Dominguez

INVOICE

73978

DATE

2-26-26

PRESENTING CLINICAL SIGNS

Abnormal PE/Chem/CBC/UA Results: Owner reports that the patient, a 7.5-year-old dog, began limping after playing fetch by the pool over the weekend. Owner states that on Sunday evening, the patient was slower retrieving the tennis ball and later that night was found in the bathroom holding up the left hind leg, not putting any weight on it. The patient has been walking gingerly on the affected leg since then.

COMPUTED TOMOGRAPHY OF THE LUMBAR SPINE, PELVIS AND STIFLE JOINTS

A high resolution pre- and post-contrast CT study of the lumbar spine, pelvis and stifle joints is provided for review.

COMPUTED TOMOGRAPHIC FINDINGS

The osseous and soft tissue structures of the lumbar spine reveal no abnormalities. The dural tube has the expected diameter and attenuation behavior without pathological contrast uptake.

The cranial pole of the left kidney presents a concave depression of the surface.

The osseous and surrounding soft tissue structures of the pelvis are within normal limits. Both coxofemoral joints present smooth osseous margins and congruent joint spaces.

The stifle joints are cropped by the field of view and evaluation is not possible.

COMPUTED TOMOGRAPHIC DIAGNOSIS

- Left sided chronic renal infarction
- Normal lumbar spine
- Normal pelvis

INTERPRETATION OF THE FINDINGS & FURTHER RECOMMENDATIONS

The CT study reveals no clinically relevant abnormalities. Unfortunately, the stifle joints are cropped by the field of view – the included parts present no overt degenerative changes.



PATIENT

Cooper Sempler

SPECIES

Canine

BREED

Cavapoo

SEX

MN

AGE

7Y, 6M

WEIGHT

28lbs

INTERPRETED BY

Sebastian Schaub, DVM
Dr. med. vet.
DipECVDI

IMAGING PERFORMED BY

Monika Salgado

HOSPITAL NAME

Westchester Animal
Hospital

REFERRING VET

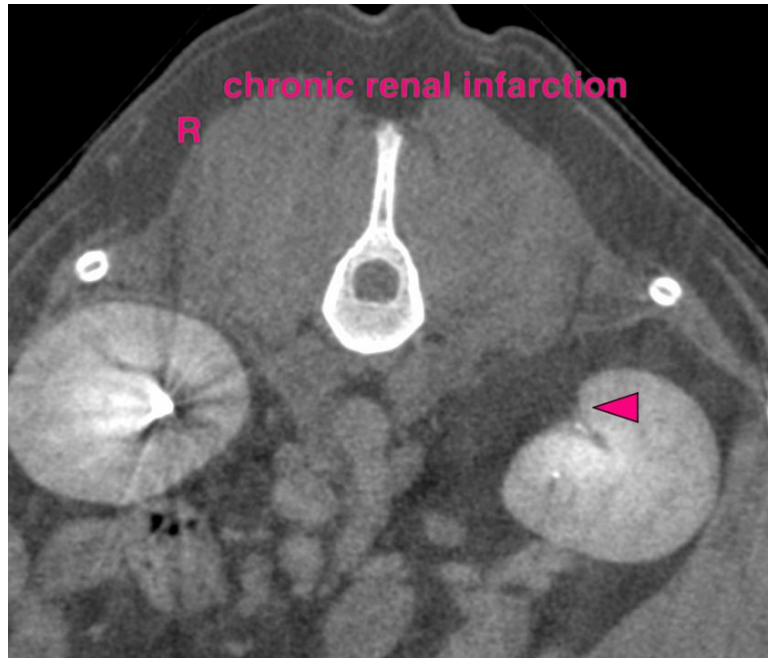
Randy Dominguez

INVOICE

73978

DATE

2-26-26



The information and recommendations provided are based on the images presented by the referring veterinarian/sonographer. No evaluation can be communicated regarding pathology that was not visible in the image/video clips provided.

Thank you for this referral. If the clinical or image interpretation does not parallel your findings or if I can be of any further assistance please contact me.

Sebastian Schaub, Sebastian Schaub, DVM, Dr. med. vet. DipECVDI
info@sonopath.com