



PATIENT

Cooper Childress

SPECIES

Canine

BREED

Great Dane

SEX

MN

AGE

7

WEIGHT

122

INTERPRETED BY

Sebastian Schaub, DVM
Dr. med. vet.
DipECVDP

IMAGING PERFORMED BY

Dr. Moser

HOSPITAL NAME

Bluegrass Animal
Hospital

REFERRING VET

Dr. Cristi Moser

INVOICE

73964

DATE

2-26-26

PRESENTING CLINICAL SIGNS

- Missing lung lobe on left side. Presented 2/25 after suspect syncopal episode.

Abnormal PE/Chem/CBC/UA Results: WNL

RADIOGRAPHIC STUDY OF THE THORAX

Radiographs of the thorax in three imaging planes are provided for review.

RADIOGRAPHIC FINDINGS

Along the thoracic spine, multifocal mild spondylosis formation is seen.

The extrathoracic soft tissues present homogeneous without abnormalities.

The heart is of normal size and shape; there is no evidence of cardiac chamber or vascular enlargement. The pulmonary vasculature is within normal limits.

The cranial mediastinum presents the expected soft tissue opacity. The mediastinal width is less than twice the width of the vertebral column at the same level.

The trachea is normal in diameter and presents the anticipated course. The luminal outline of the trachea is smooth. Two mineral opaque surgical clips are superimposed on the hilar region of the lung.

The bronchial tree presents with thin walls and tapers uniformly towards the periphery as expected.

The lung parenchyma presents the expected architecture and opacity; the intrapulmonary vascular branching is seen up to the third order lung vessels.

The left crus of the diaphragm is in a mild relative cranial position.

RADIOGRAPHIC DIAGNOSIS

- History of lobectomy left lung lobe – suspect left caudal lung lobe
- Spondylosis deformans

INTERPRETATION OF THE FINDINGS & FURTHER RECOMMENDATIONS

The radiographic study reveals no clinically relevant abnormalities, an underlying cause for the syncopal episode cannot be specified.



PATIENT

Cooper Childress

SPECIES

Canine

BREED

Great Dane

SEX

MN

AGE

7

WEIGHT

122

INTERPRETED BY

Sebastian Schaub, DVM
Dr. med. vet.
DipECVDI

IMAGING PERFORMED BY

Dr. Moser

HOSPITAL NAME

Bluegrass Animal
Hospital

REFERRING VET

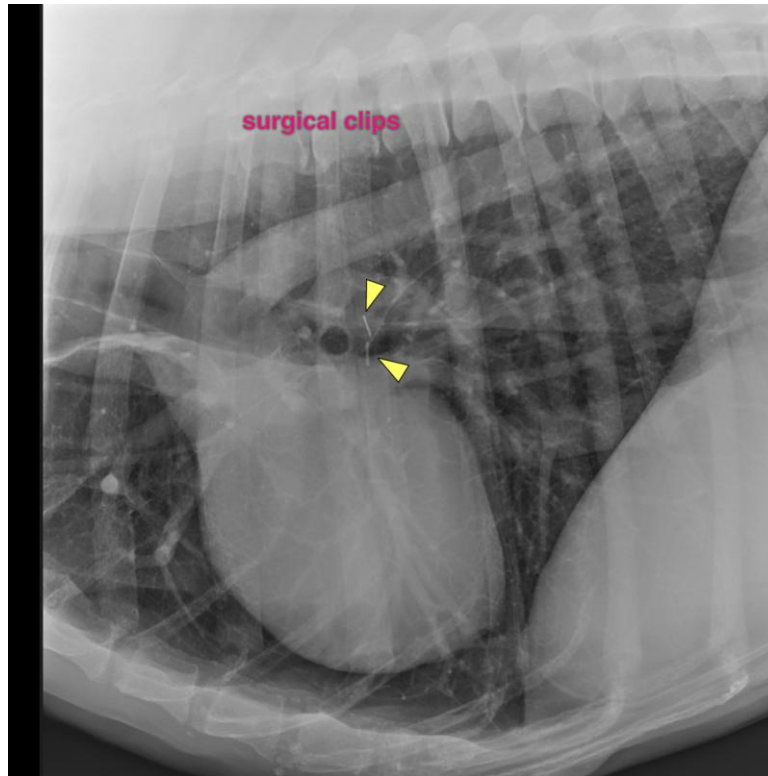
Dr. Cristi Moser

INVOICE

73964

DATE

2-26-26



The information and recommendations provided are based on the images presented by the referring veterinarian/sonographer. No evaluation can be communicated regarding pathology that was not visible in the image/video clips provided.

Thank you for this referral. If the clinical or image interpretation does not parallel your findings or if I can be of any further assistance please contact me.

Sebastian Schaub, Sebastian Schaub, DVM, Dr. med. vet. DipECVDI
info@sonopath.com