



PATIENT PRESENTING CLINICAL SIGNS

Lucky Sato S: Here for a wellness exam and blood work. O wants us to take a look at teeth, P looks like is in pain when eating hard hard. d/u/d ok no c/s/v/d no other concerns. O: BAR, mm-pink, CRT<2sec, EENT, teeth- severe tartar, H/L, Abdo, U/G, skin and coat- small hard masses between RM3 and RM4 and another small by RM3 A: mammary gland masses
 Abnormal PE/Chem/CBC/UA Results: Diag- ALP 175 CBC- WNL T4- 3.0 4dx test- Negative CPL- Normal

SPECIES

Canine

BREED

Papillon

RADIOGRAPHIC STUDY OF THE THORAX & ABDOMEN

A complete set of radiographs of the thorax and abdomen is provided for review.

RADIOGRAPHIC FINDINGS

SEX

Female

Thorax

The surrounding bony structures are within normal limits.

The extrathoracic soft tissues present homogeneous without abnormalities.

AGE

12

The heart is of normal size and shape, there is no evidence of cardiac chamber or vascular enlargement. The pulmonary vasculature is within normal limits.

INTERPRETED BY

Sebastian Schaub, DVM
 Dr. med. vet. DipECVDI

The cranial mediastinum presents the expected soft tissue opacity. The mediastinal width is less than twice the width of the vertebral column at the same level.

The trachea is normal in diameter and presents the anticipated course. The luminal outline of the trachea is smooth.

HOSPITAL NAME

Animal Paradise
 Hospital

The bronchial tree presents with thin walls and tapers uniformly towards the periphery as expected.

The lung parenchyma presents the expected architecture and opacity; the intrapulmonary vascular branching is seen up to the third order lung vessels.

REFERRING VET

Dr. Mostafa Elshafie

The diaphragm is well delineated with even surface and the expected mild cranial bulging of the diaphragmatic cupola.

Abdomen

INVOICE

50582

Multifocal moderate spondylosis formation is seen along the lumbar spine.

The abdominal wall is smooth and thin. In the right inguinal cutaneous fold, a small nodular mineralization is visible.

DATE

2-26-22

The serosal detail is maintained throughout the peritoneal and retroperitoneal space.

The liver is appropriate in position, size and presents uniform opacity.

The splenic head is in the anticipated position and within normal limits for size and opacity. The



PATIENT

splenic body and tail are considered normal for position, size, shape and opacity.

Lucky Sato

Both kidneys are seen and present with normal size, shape, delineation and opacity. The urinary bladder is in its anticipated position. No radiopaque calculi are noted throughout the upper and lower urinary tract.

SPECIES

The stomach is in its anticipated position and presents normal content.

Canine

The small intestinal loops are of even diameter and non-dilated, a small amount of gas is seen within the small intestinal loops and considered within normal limits.

BREED

The colon is seen in the expected position and presents with appropriate content.

Papillon

RADIOGRAPHIC DIAGNOSIS

SEX

- Spondylosis deformans lumbar spine
- Subcutaneous dystrophic mineralization right inguinal region.
- Normal thorax

Female

INTERPRETATION OF THE FINDINGS & FURTHER RECOMMENDATIONS

AGE

The radiographic study of the thorax & abdomen presents without clinically relevant abnormalities.

12

INTERPRETED BY

Sebastian Schaub, DVM
Dr. med. vet. DipECVDI

HOSPITAL NAME

Animal Paradise
Hospital

REFERRING VET

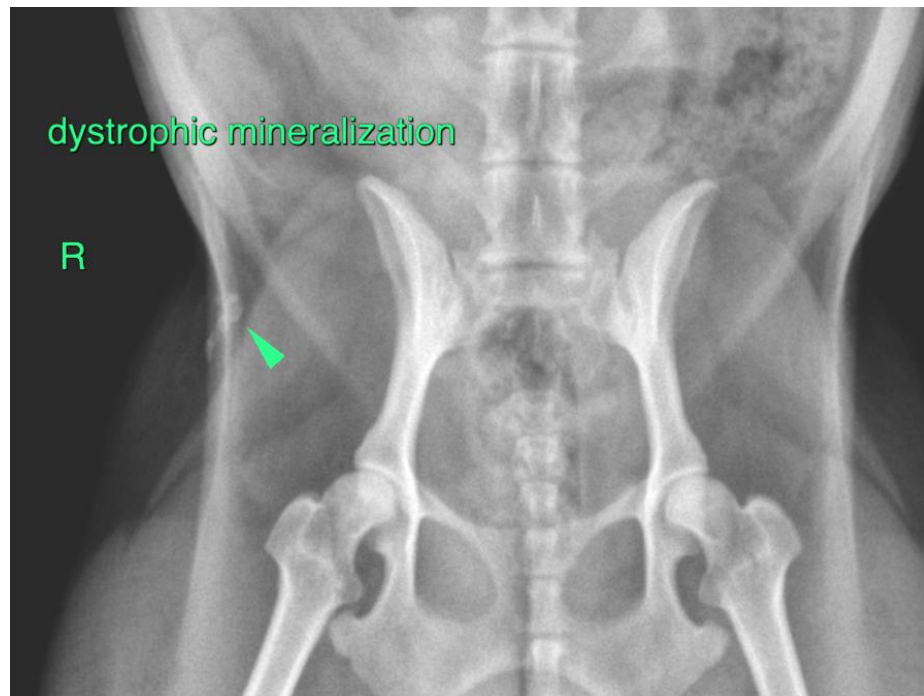
Dr. Mostafa Elshafie

INVOICE

50582

DATE

2-26-22





PATIENT

Lucky Sato

SPECIES

Canine

BREED

Papillon

SEX

Female

AGE

12

INTERPRETED BY

Sebastian Schaub, DVM
Dr. med. vet. DipECVDI

HOSPITAL NAME

Animal Paradise
Hospital

REFERRING VET

Dr. Mostafa Elshafie

INVOICE

50582

DATE

2-26-22

The information and recommendations provided are based on the images presented by the referring veterinarian/sonographer. No evaluation can be communicated regarding pathology that was not visible in the image/video clips provided.

Thank you for this referral. If the clinical or image interpretation does not parallel your findings or if I can be of any further assistance please contact me.

Sebastian Schaub, Sebastian Schaub, DVM, Dr. med. vet. DipECVDI
sebast.schaub@gmail.com