



PATIENT PRESENTING CLINICAL SIGNS

SJ Creehan History: dental imaging being sent for consult

COMPUTED TOMOGRAPHIC STUDY OF THE SKULL

SPECIES

Canine A high-resolution plain CT study of the skull is provided for review.

COMPUTED TOMOGRAPHIC FINDINGS

BREED

Yorkie

The tooth elements 105, 110, 209, 210, 310, 311 and 411 are absent. Triadan 305 is retained within the alveolar bone without evidence of cyst formation. The mesial and distal root of triadan 306 presents a transverse fracture. Triadan 308 presents a moderate to marked widening of the periodontal space. A generalized mild horizontal bone loss is seen in all jaw quadrants.

SEX

Neutered Male

The nasal cavity presents the expected aerated spaces between thin & even conchae and turbinates with smooth mucosal lining.

AGE

11 Years

Both temporomandibular joints present congruent joint spaces with even subchondral bone surfaces and are

COMPUTED TOMOGRAPHIC DIAGNOSIS

- Moderate periodontal disease 308
- Generalized mild periodontal disease of the remaining teeth
- Fractured roots triadan 306
- Unerupted triadan 305
- Absent tooth elements 105, 110, 209, 210, 310, 311 and 411

INTERPRETED BY

Sebastian Schaub,
DVM Dr. med. vet.
DipECVDI

INTERPRETATION OF THE FINDINGS & FURTHER RECOMMENDATIONS

HOSPITAL NAME

Cranberry Holistic PC

There is evidence of generalized mild periodontal disease. Triadan 308 presents with advanced periodontal disease.

REFERRING VET

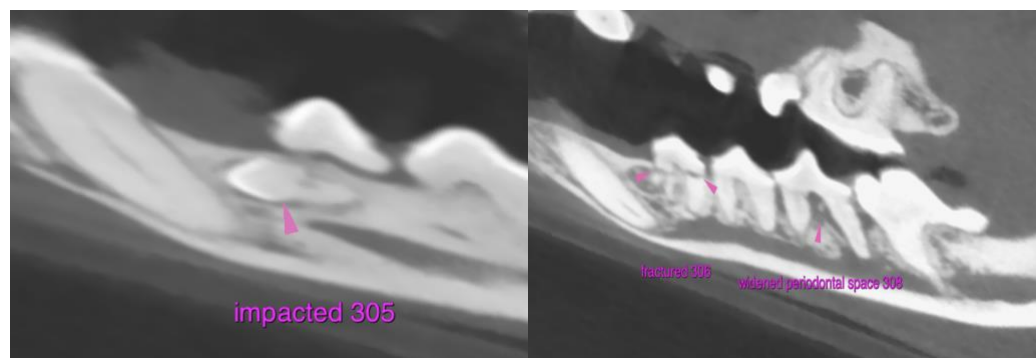
Dr. Cynthia Maro

INVOICE

14099

DATE

2/25/22





PATIENT The information and recommendations provided are based on the images presented by the referring veterinarian/sonographer. No evaluation can be communicated regarding pathology that was not visible in the image/video clips provided.

SJ Creehan

Thank you for this referral. If the clinical or image interpretation does not parallel your findings or if I can be of any further assistance please contact me.

SPECIES

Canine

Sebastian Schaub, Sebastian Schaub, DVM, Dr. med. vet. DipECVDI
sebast.schaub@gmail.com

BREED

Yorkie

SEX

Neutered Male

AGE

11 Years

INTERPRETED BY

Sebastian Schaub,
DVM Dr. med. vet.
DipECVDI

HOSPITAL NAME

Cranberry Holistic PC

REFERRING VET

Dr. Cynthia Maro

INVOICE

14099

DATE

2/25/22