



**PATIENT PRESENTING CLINICAL SIGNS**

Mercy Chadwick History: 1 week history of lameness on her RPL. No obvious event led to the lameness. It has improved with rest.

**SPECIES RADIOGRAPHIC STUDY OF THE PELVIS AND STIFLE JOINTS**

Canine Radiographs of the pelvis and stifle joints in orthogonal imaging planes are provided for review.

**RADIOGRAPHIC FINDINGS**

**BREED**

GSD Multifocal moderate spondylosis formation is seen along the lumbar spine and the facet joints of the lumbar spine present with osteophyte new bone formation.

**SEX**

Spayed Female Both coxofemoral joints present mild osteophyte new bone formation.

**AGE**

S1 is not fused with S2.

Both stifle joints present moderate osteophyte new bone formation and a mild to moderate intracapsular soft tissue swelling – distorting the infrapatellar fat pad and fascial plane caudally.

**RADIOGRAPHIC DIAGNOSIS**

11 Years 2 Months

- Moderate degenerative osteoarthritis & articular swelling stifle joints bilaterally
- Mild degenerative osteoarthritis coxofemoral joints bilaterally
- Serial spondylarthrosis lumbar spine
- Spondylosis deformans
- Symmetric lumbosacral transitional vertebra (Type II)

**INTERPRETED BY**

Sebastian Schaub,  
DVM Dr. med. vet.  
DipECVDI

**INTERPRETATION OF THE FINDINGS & FURTHER RECOMMENDATIONS**

**HOSPITAL NAME**

Tahoe Integrative VC

The radiographic study is consistent with chronic degenerative osteoarthritis with concomitant joint effusion of both stifle joints. The most-likely underlying cause is (partial) rupture of the cranial cruciate ligament with or without meniscal disease.

**REFERRING VET**

Dr. Amanda Stuart

A positive drawer sign or tibial compression test under general anesthesia can be used to confirm the diagnosis.

The degenerative changes along the lumbosacral junction in combination with the lumbosacral transitional vertebra can predispose for degenerative lumbosacral stenosis.

**INVOICE**

14101

**DATE**

2/25/22



**PATIENT**

Mercy Chadwick

**SPECIES**

Canine

**BREED**

GSD

**SEX**

Spayed Female

**AGE**

11 Years 2 Months

**INTERPRETED BY**

Sebastian Schaub,  
DVM Dr. med. vet.  
DipECVDI

**HOSPITAL NAME**

Tahoe Integrative VC

**REFERRING VET**

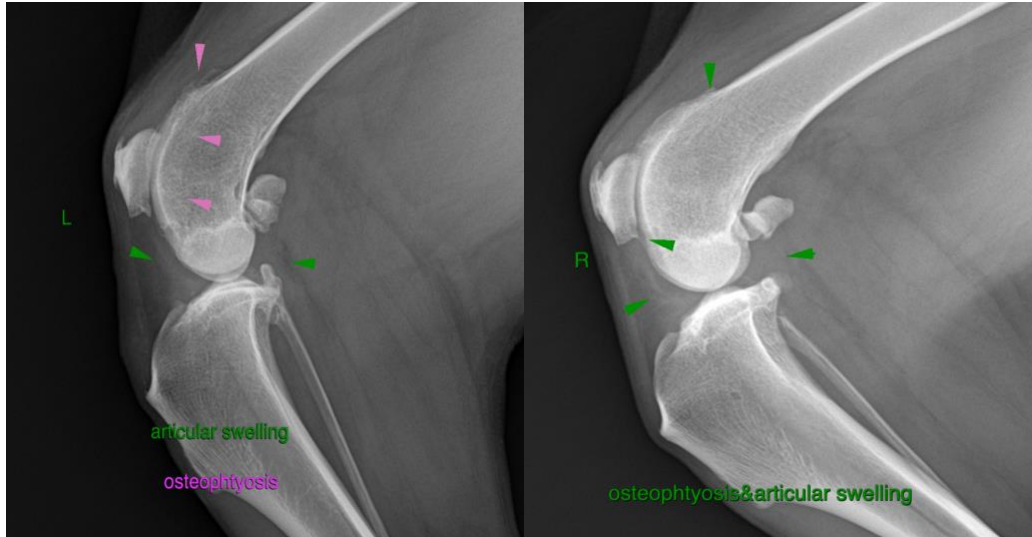
Dr. Amanda Stuart

**INVOICE**

14101

**DATE**

2/25/22



**The information and recommendations provided are based on the images presented by the referring veterinarian/sonographer. No evaluation can be communicated regarding pathology that was not visible in the image/video clips provided.**

Thank you for this referral. If the clinical or image interpretation does not parallel your findings or if I can be of any further assistance please contact me.

**Sebastian Schaub**, Sebastian Schaub, DVM, Dr. med. vet. DipECVDI  
sebast.schaub@gmail.com