



**PATIENT PRESENTING CLINICAL SIGNS**

Max Kalra History: Max has been coughing on and off for the past 2 years. Coughing got worse in the past month, almost every day. Otherwise, no concerns

**SPECIES** Abnormal PE/Chem/CBC/UA Results: b/w from previous vet was in normal limits

Canine **RADIOGRAPHIC STUDY OF THE THORAX**

Radiographs of the thorax in three imaging planes are provided for review.

**BREED RADIOGRAPHIC FINDINGS**

Shih Tzu X  
The body condition score is 8/9.

**SEX** The surrounding bony structures are within normal limits.

Neutered Male The extrathoracic soft tissues present homogeneous without abnormalities.

**AGE** The heart is of normal size and shape, there is no evidence of cardiac chamber or vascular enlargement. The pulmonary vasculature is within normal limits.

7 Years The cranial mediastinum presents the expected soft tissue opacity. The mediastinal width is less than twice the width of the vertebral column at the same level.

**INTERPRETED BY** A soft tissue membrane is bulging ventrally into the lumen of the cervical tracheal segment.

Sebastian Schaub, DVM Dr. med. vet. DipECVDI  
The bronchial tree presents with thin walls and tapers uniformly towards the periphery as expected. The lung parenchyma presents the expected architecture and opacity; the intrapulmonary vascular branching is seen up to the third order lung vessels.

**HOSPITAL NAME** The diaphragm is well delineated with even surface and the expected mild cranial bulging of the diaphragmatic cupola.  
Truscott AH

**RADIOGRAPHIC DIAGNOSIS**

**REFERRING VET**

- Obesity
- Redundant tracheal membrane

Dr. Erini Abraham

**INTERPRETATION OF THE FINDINGS & FURTHER RECOMMENDATIONS**

**INVOICE** The redundant tracheal membrane can be a precursor for tracheal collapse.  
14102

The lung parenchyma presents without radiographic changes, however negative radiographs do not rule out possible tracheitis/bronchitis. If clinical signs are refractory to empirical management, bronchoscopy including BAL can be used as advanced diagnostic test.

**DATE**

2/25/22



**PATIENT**

Max Kalra

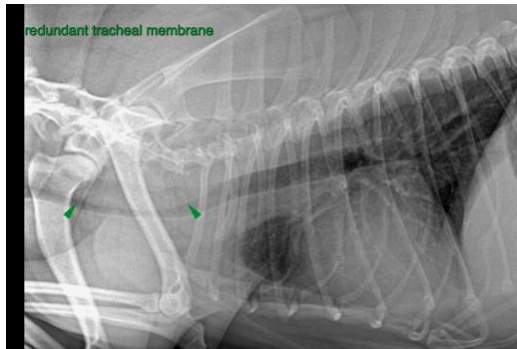
Obesity is also a known predisposing factor for cough and weight management appears beneficial.

**SPECIES**

Canine

**BREED**

Shih Tzu X



**SEX**

Neutered Male

**The information and recommendations provided are based on the images presented by the referring veterinarian/sonographer. No evaluation can be communicated regarding pathology that was not visible in the image/video clips provided.**

**AGE**

7 Years

Thank you for this referral. If the clinical or image interpretation does not parallel your findings or if I can be of any further assistance please contact me.

**Sebastian Schaub**, Sebastian Schaub, DVM, Dr. med. vet. DipECVDI  
sebast.schaub@gmail.com

**INTERPRETED BY**

Sebastian Schaub,  
DVM Dr. med. vet.  
DipECVDI

**HOSPITAL NAME**

Truscott AH

**REFERRING VET**

Dr. Erini Abraham

**INVOICE**

14102

**DATE**

2/25/22