



PATIENT PRESENTING CLINICAL SIGNS

Lucky Karrman History: Lucky was howling early this morning; O came out to see what he was doing. He was staring at the wall, eyes darting back and forth. O went to pet him and he fell off the cat tree. He did not land on his feet. He has been walking around disoriented, looks dizzy, loss of balance. Shaking head back and forth, eyes moving back as forth. He does have a history of ear infections.
SPECIES Abnormal PE/Chem/CBC/UA Results: NYSTAGMUS INCREASED LACTATE 4.65

Feline

COMPUTED TOMOGRAPHIC STUDY OF THE SKULL

BREED A high resolution pre- and post-contrast CT study of the skull is provided for review.

DSH COMPUTED TOMOGRAPHIC FINDINGS

The pictured parts of the dentition are complete and unremarkable in all jaw quadrants.

SEX

Neutered Male The nasal cavity presents the expected aerated spaces between thin & even conchae and turbinates with smooth mucosal lining.

AGE

8 Years Both temporomandibular joints present congruent joint spaces with even subchondral bone surfaces and are considered within normal limits.

INTERPRETED BY

Sebastian Schaub,
DVM Dr. med. vet.
DipECVDI

The right tympanic bulla presents a moderately increased volume and the osseous lining is significantly thickened and irregular with multifocal moth eaten osteolytic lesions. The right tympanic bulla is filled with soft tissue attenuating and peripheral contrast enhancing material. The osseous segment of the right auditory tube is mildly widened and a soft tissue swelling is seen in the region of the orifice of the right auditory tube in the nasopharynx. Moth eaten osteolytic lesions of the tympanic part of the right temporal bone are noted and post contrast administration there is moderate contrast enhancement and thickening of the meninges at the same level. The left tympanic bulla is moderately filled with soft tissue attenuating material and the mucosal lining of the left tympanic bulla is moderately thickened.

HOSPITAL NAME

Animal Emergency
Hospital, Volusia

The submandibular and medial retropharyngeal lymph nodes are prominent with a normal short-to-long-axis-ratio is < 0.5, the attenuation and contrast enhancement pattern is uniform.

COMPUTED TOMOGRAPHIC DIAGNOSIS

REFERRING VET

Dr. Alyssa Carver

- Otitis media bilaterally, R>>L, with chronic osseous remodeling of the right tympanic bulla and signs for right sided meningitis
- Lymphadenopathy mandibular and medial retropharyngeal lymph nodes

INVOICE

14088

INTERPRETATION OF THE FINDINGS & FURTHER RECOMMENDATIONS

The findings are consistent with right sided advanced chronic otitis media with osseous remodeling of the osseous lining and signs for inflammation translocating through the tympanic part of the right

DATE

2/25/22



PATIENT

Lucky Karrman

temporal bone – presenting signs for meningitis. The soft tissue swelling level with the orifice of the right auditory tube can be secondary inflammatory or present small inflammatory polyp formation. Ventral bulla osteotomy is considered as the therapy of choice in combination with antimicrobial therapy crossing the blood-brain-barrier.

SPECIES

Feline

The odds for reactive hyperplasia of the tributary lymph nodes of the skull are high – FNA sampling can be used to confirm the diagnosis.

BREED

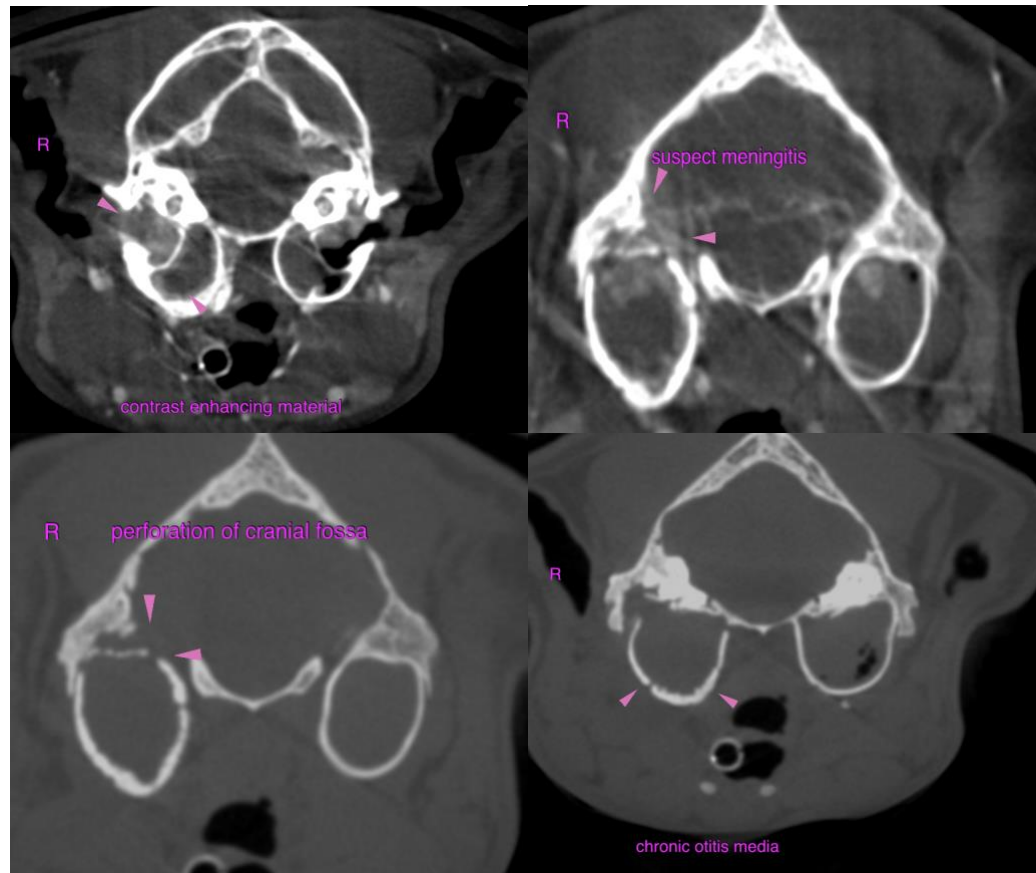
DSH

SEX

Neutered Male

AGE

8 Years



INTERPRETED BY

Sebastian Schaub,
DVM Dr. med. vet.
DipECVDI

HOSPITAL NAME

Animal Emergency
Hospital, Volusia

REFERRING VET

Dr. Alyssa Carver

The information and recommendations provided are based on the images presented by the referring veterinarian/sonographer. No evaluation can be communicated regarding pathology that was not visible in the image/video clips provided.

Thank you for this referral. If the clinical or image interpretation does not parallel your findings or if I can be of any further assistance please contact me.

INVOICE

14088

Sebastian Schaub, Sebastian Schaub, DVM, Dr. med. vet. DipECVDI
sebast.schaub@gmail.com

DATE

2/25/22



PATIENT

Lucky Karrman

SPECIES

Feline

BREED

DSH

SEX

Neutered Male

AGE

8 Years

INTERPRETED BY

Sebastian Schaub,
DVM Dr. med. vet.
DipECVDI

HOSPITAL NAME

Animal Emergency
Hospital, Volusia

REFERRING VET

Dr. Alyssa Carver

INVOICE

14088

DATE

2/25/22