



PATIENT PRESENTING CLINICAL SIGNS

Herbal Spahn History: Herbal has been limping on and off for the past month or so. Not sure how he hurt his leg but he does have seizures before and rough houses sometimes. He has been holding it up for about a week now.

SPECIES

Canine Abnormal PE/Chem/CBC/UA Results: Mucous Membranes Pink, moist, CRT <2 seconds Hydration Adequate based on mucous membranes and skin turgor. Abdomen Soft, nonpainful, no masses, no organomegaly. Rectal examination not performed. Cardiovascular/ Respiratory No murmur or arrhythmia. Lungs auscult normally. Eupnic. Eye, Ears, Nose, Throat No nasal or ocular discharge.

BREED

Boxer Mix Normal examination. Genitourinary No discharge or irritation. No anal gland enlargement. Lymph Nodes No enlargement. Musculoskeletal RH NWB. RIGHT STIFLE EFFUSION AND CRANIAL DRAWER Ambulatory X 3. Neck, spine, and tail are normal. No loss of proprioception. Neurologic Alert, normal cranial nerve function. Oral Normal examination Skin / Coat No masses. Full healthy hair coat.

SEX

Neutered Male

RADIOGRAPHIC STUDY OF THE PELVIS AND STIFLE JOINTS

A VD projection of the pelvis and radiographs of the stifle joints in two imaging planes are provided for review.

AGE

2 Years

RADIOGRAPHIC FINDINGS

The osseous and surrounding soft tissue structures of the pelvis are within normal limits. The coxofemoral joints present a congruent joint space and smooth osseous margins.

INTERPRETED BY

Sebastian Schaub,
DVM Dr. med. vet.
DipECVDI

The volume of the right thigh musculature is moderately decreased.

The right stifle joint present mild osteophyte new bone formation and a marked intracapsular soft tissue swelling, effacing the infrapatellar fat pad and distorting the fascial plane caudally.

HOSPITAL NAME

Elizabeth AH

The left stifle joint presents smooth osseous margins and no signs for intracapsular swelling.

RADIOGRAPHIC DIAGNOSIS

REFERRING VET

Dr. Leon Anderson

- Mild degenerative osteoarthritis left stifle joint and marked articular swelling right stifle joint
- Disuse atrophy right thigh musculature
- Normal pelvis
- Normal left stifle joint

INVOICE

14104

INTERPRETATION OF THE FINDINGS & FURTHER RECOMMENDATIONS

The radiographic study is consistent with mild chronic degenerative osteoarthritis with concomitant joint effusion of the right stifle joint. The most-likely underlying cause is (partial) rupture of the cranial cruciate ligament with or without meniscal disease.

DATE

2/25/22



PATIENT

A positive drawer sign or tibial compression test under general anesthesia can be used to confirm the diagnosis.

Herbal Spahn

SPECIES

Canine

BREED

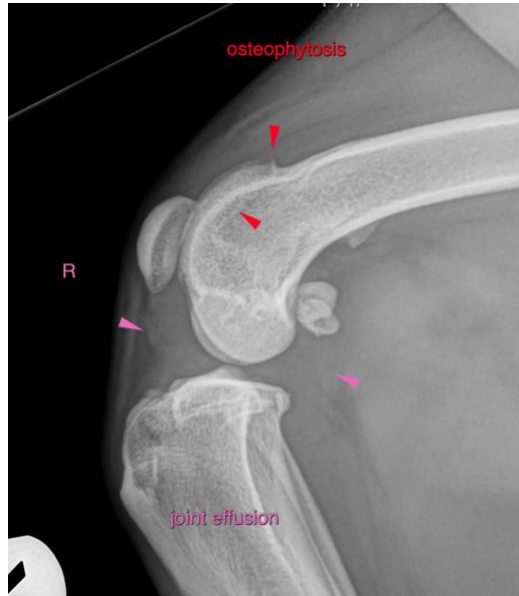
Boxer Mix

SEX

Neutered Male

AGE

2 Years



INTERPRETED BY

Sebastian Schaub,
DVM Dr. med. vet.
DipECVDI

The information and recommendations provided are based on the images presented by the referring veterinarian/sonographer. No evaluation can be communicated regarding pathology that was not visible in the image/video clips provided.

Thank you for this referral. If the clinical or image interpretation does not parallel your findings or if I can be of any further assistance please contact me.

HOSPITAL NAME

Elizabeth AH

Sebastian Schaub, Sebastian Schaub, DVM, Dr. med. vet. DipECVDI
sebast.schaub@gmail.com

REFERRING VET

Dr. Leon Anderson

INVOICE

14104

DATE

2/25/22