



PATIENT PRESENTING CLINICAL SIGNS

Pepper Stephen History: Lethargic, decreased appetite for about a week. Jumped off the couch suddenly and since then she has been shaking, limping on and off on the LHL that seems to have resolved. Still seems lethargic with decreased appetite. No CVSD. No PU/PD.

SPECIES

Canine Abnormal PE/Chem/CBC/UA Results: Slight pale mm. No pain on palpating of bones, ROM of joints are normal. Soft abdomen, no pain elicited. Note: Sedation wasn't given because of the increased liver values (ALT and ALKP), so ACL wasn't checked under sedation. BW attached

BREED RADIOGRAPHIC STUDY OF THE ABDOMEN AND STIFLE JOINTS

French Bulldog X A complete set of radiographs of the abdomen and the stifle joints is provided for review.

SEX RADIOGRAPHIC FINDINGS

SEX

Spayed Female **Abdomen**

AGE

7 Years

Multiple hemiverte. The intervertebral disc spaces L1/L2 and L2/L3 are collapsed and the subchondral bone of the respective vertebral endplates presents moderate sclerosis and ventral spondylosis formation. Irregular mineral opaque material is superimposed on the neuroforamina L1/L2, L2/L3 and L6/L7.

No abnormalities of the extraabdominal soft tissues are noted. The abdominal wall is smooth and thin.

INTERPRETED BY

Sebastian Schaub,
DVM Dr. med. vet.
DipECVDI

The serosal detail is maintained throughout the peritoneal and retroperitoneal space.

The liver is appropriate in position, size and presents uniform opacity.

HOSPITAL NAME

Truscott AH

The splenic head is in the anticipated position and within normal limits for size and opacity. The caudal extremity of the spleen presents mild undulating margins.

Both kidneys are seen and present with normal size, shape, delineation and opacity. The urinary bladder is in its anticipated position. No radiopaque calculi are noted throughout the upper and lower urinary tract.

REFERRING VET

Dr. Erini Abraham

The stomach is in its anticipated position and presents normal content.

INVOICE

21294

The small intestinal loops are of even diameter and non-dilated, a small amount of gas is seen within the small intestinal loops and considered within normal limits.

The colon is seen in the expected position and presents with appropriate content.

DATE

2/24/23

Stifle Joints



PATIENT

Pepper Stephen

The stifle joints present smooth osseous margins and without signs of intracapsular soft tissue swelling. The patella of both stifle joints is in situ. The surrounding soft tissue structures of the stifle joints are within normal limits.

SPECIES

Canine

RADIOGRAPHIC DIAGNOSIS

- Chronic discopathy L1/L2 and L2/L3 with spondylosis formation and mineralized material superimposed on the respective neuroforamen
- Small amount of mineralized material superimposed on the neuroforamen L6/L7
- Mild undulating margins caudal extremity of the spleen
- Multiple hemivertebra caudal thoracic spine
- Normal stifle joints

BREED

French Bulldog X

INTERPRETATION OF THE FINDINGS & FURTHER RECOMMENDATIONS

SEX

Spayed Female

The chronic discopathy L1/L2 and L2/L3 and the mineralized material superimposed on the respective neuroforamen can present either lateral spondylosis formation or mineralized disc material bulging into the vertebral canal. Acute on chronic disc disease might be a source for the described clinical signs.

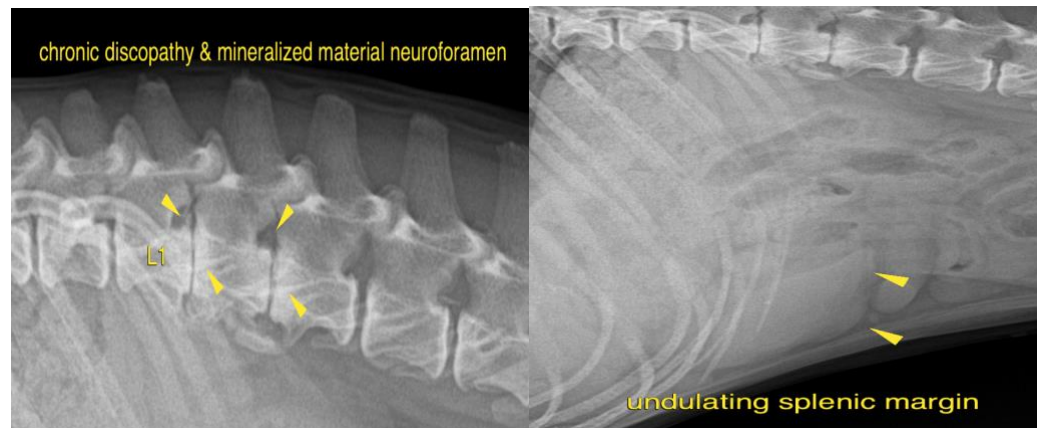
AGE

7 Years

The undulating margins of the spleen can be a sequel to the positioning of the spleen, however an intraparenchymal nodule is a consideration – such as nodular hyperplasia, hematoma, neoplasia. Ultrasound can be used to rule out splenic parenchymal lesion.

INTERPRETED BY

Sebastian Schaub,
DVM Dr. med. vet.
DipECVDI



HOSPITAL NAME

Truscott AH

REFERRING VET

Dr. Erini Abraham

The information and recommendations provided are based on the images presented by the referring veterinarian/sonographer. No evaluation can be communicated regarding pathology that was not visible in the image/video clips provided.

INVOICE

21294

Thank you for this referral. If the clinical or image interpretation does not parallel your findings or if I can be of any further assistance please contact me.

DATE

2/24/23



PATIENT

Pepper Stephen

Sebastian Schaub, Sebastian Schaub, DVM, Dr. med. vet. DipECVDI
sebast.schaub@gmail.com

SPECIES

Canine

BREED

French Bulldog X

SEX

Spayed Female

AGE

7 Years

INTERPRETED BY

Sebastian Schaub,
DVM Dr. med. vet.
DipECVDI

HOSPITAL NAME

Truscott AH

REFERRING VET

Dr. Erini Abraham

INVOICE

21294

DATE

2/24/23