



PATIENT

Remi Rae Roper
Weeks

SPECIES

Canine

BREED

Blue Heeler

SEX

Male

AGE

5M

WEIGHT

24lbs

INTERPRETED BY

Sebastian Schaub, DVM
Dr. med. vet.
DipECVDI

IMAGING PERFORMED BY

Bill McGee, DVM,
DABVP

HOSPITAL NAME

Bridgeport Animal
Hospital PLLC

REFERRING VET

Bill McGee, DVM,
DABVP

INVOICE

73909

DATE

2-23-26

PRESENTING CLINICAL SIGNS

chronic left forelimb lameness

COMPUTED TOMOGRAPHY OF THE SHOULDER AND ELBOW JOINTS

A high resolution plain CT study of the front limbs is provided for review.

COMPUTED TOMOGRAPHIC FINDINGS

The growth plates are age related visible.

Both shoulder joints present smooth margins of the periarticular bones and the surrounding soft tissue structures are within normal limits.

The osseous surfaces of both elbow joints are smooth. The cranial tip of the medial coronoid process of the left elbow joint is demarcated by mild curved, craniomedially to caudolaterally directed, ill-defined fissure line. At the cranial aspect of the medial coronoid process of the left elbow joint a triangular shaped isolated mineral attenuating body is seen; measuring <2 mm. The joint space of both elbow joints is congruent. The medial coronoid process of the right elbow joint is well-defined and has a homogeneous density.

COMPUTED TOMOGRAPHIC DIAGNOSIS

- Fragmented medial coronoid process (FCP) left elbow joint
- Normal right elbow joint
- Normal shoulder joints

INTERPRETATION OF THE FINDINGS & FURTHER RECOMMENDATIONS

The CT findings are consistent with left sided elbow dysplasia – a plausible explanation for left front limb lameness. Arthroscopy/arthrotomy would be ideal to revise the affected elbow joint and remove the osseous fragment/nonvital tip of the medial coronoid process to avoid further damage.



PATIENT

Remi Rae Roper
Weeks

SPECIES

Canine

BREED

Blue Heeler

SEX

Male

AGE

5M

WEIGHT

24lbs

INTERPRETED BY

Sebastian Schaub, DVM
Dr. med. vet.
DipECVDI

IMAGING PERFORMED BY

Bill McGee, DVM,
DABVP

HOSPITAL NAME

Bridgeport Animal
Hospital PLLC

REFERRING VET

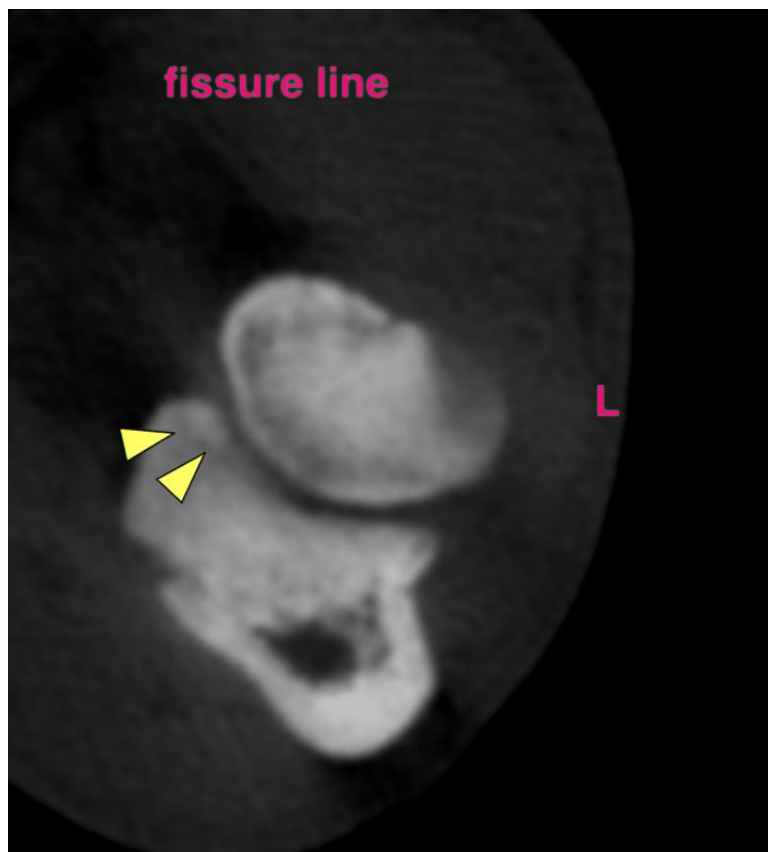
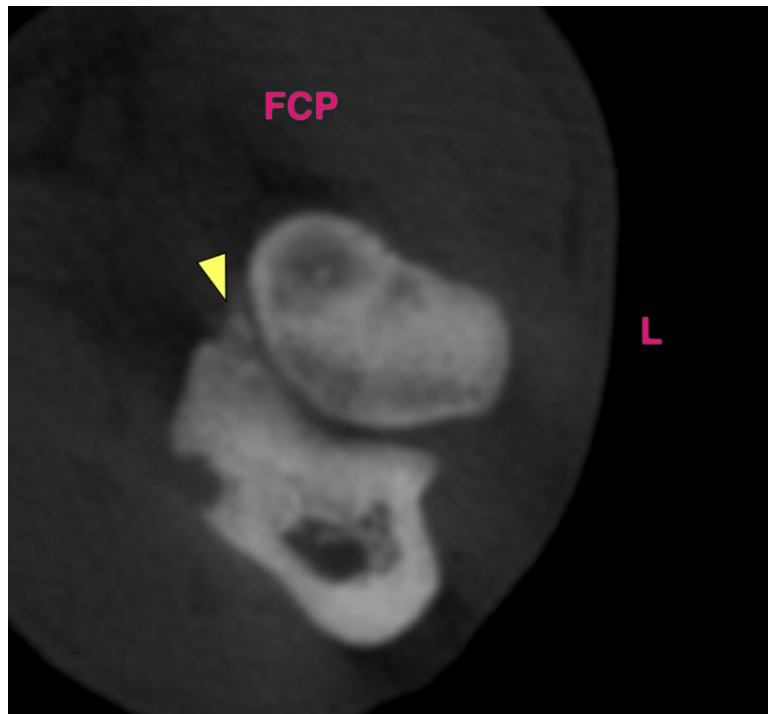
Bill McGee, DVM,
DABVP

INVOICE

73909

DATE

2-23-26





PATIENT

Remi Rae Roper
Weeks

SPECIES

Canine

BREED

Blue Heeler

SEX

Male

AGE

5M

WEIGHT

24lbs

INTERPRETED BY

Sebastian Schaub, DVM
Dr. med. vet.
DipECVDI

IMAGING PERFORMED BY

Bill McGee, DVM,
DABVP

HOSPITAL NAME

Bridgeport Animal
Hospital PLLC

REFERRING VET

Bill McGee, DVM,
DABVP

INVOICE

73909

DATE

2-23-26

The information and recommendations provided are based on the images presented by the referring veterinarian/sonographer. No evaluation can be communicated regarding pathology that was not visible in the image/video clips provided.

Thank you for this referral. If the clinical or image interpretation does not parallel your findings or if I can be of any further assistance please contact me.

Sebastian Schaub, Sebastian Schaub, DVM, Dr. med. vet. DipECVDI
info@sonopath.com