



PATIENT PRESENTING CLINICAL SIGNS

Molly Gutter Increased liver values on pre-dental lab work; confirmed 2 weeks later on re-draw; AUS showed >4cm mass in liver; FNA of mass consistent with a well-differentiated hepatocellular neoplasm (hepatocellular carcinoma vs. hepatoma)

SPECIES COMPUTED TOMOGRAPHY OF THE THORAX AND ABDOMEN

Canine A high resolution pre- and post-contrast CT study of the abdomen and a post-contrast CT study of the thorax are provided for review.

BREED COMPUTED TOMOGRAPHIC FINDINGS

Border Collie Thorax

The bony and surrounding soft tissue structures are within normal limits.

SEX The sternal, cranial mediastinal and tracheobronchial lymph nodes are small elongated with a normal short-to-long-axis-ratio is < 0.5, the attenuation and contrast enhancement pattern is uniform and considered within normal limits.

Spayed Female

The cardiovascular structures including the pulmonary vasculature are within normal limits.

AGE The bronchial tree presents with regular branching and tapers uniformly towards the periphery as expected, the bronchial walls are thin and smooth. The bronchus-to-artery ratio is within normal limits.

6 Years

The lung parenchyma presents the expected architecture and attenuation behavior.

INTERPRETED BY Small incidental gas pockets are seen within the esophageal lumen, there is no evidence of abnormal dilation.

Sebastian Schaub, DVM
Dr. med. vet. DipECVDI

Abdomen

HOSPITAL NAME The serosal fat presents normal attenuation behavior. There is no evidence of peritoneal effusion or peritonitis.

Mobile Pet Imaging

Both kidneys present within normal limits for size, shape and organ architecture. After contrast administration a bilaterally symmetric and uniform nephro- and pyelogram is noted.

REFERRING VET The adrenal glands are within normal limits for size, shape and organ architecture.

Meaux

The spleen presents with normal shape, even surface, uniformly attenuating parenchyma and homogeneous contrast enhancement, unremarkable.

INVOICE In the dorsal aspect of the left medial liver lobe, a post contrast heterogeneous contrast enhancing ovoidal shaped mass is seen, measuring 4.6 x 3.1 x 3.3 cm in size and mildly bulging beyond the hepatic surface. A second heterogeneous contrast enhancing lesion is seen ventrally in the parenchyma of the left lateral liver lobe, measuring 11 mm in diameter. A third mild heterogeneous contrast enhancing lesion is seen deep in the right medial liver lobe. The remainder of the hepatic parenchyma are uniform soft tissue attenuating and contrast enhancing.

56910

DATE

2-23-23

The pancreas is evenly contoured, the pancreatic parenchyma is homogeneous and presents uniform contrast enhancement.

The position, delineation, wall and content of the gastrointestinal tract are considered within normal limits throughout.



PATIENT The bony and surrounding soft tissue structures reveal no abnormalities.

Molly Gutter

COMPUTED TOMOGRAPHIC DIAGNOSIS

- Left divisional hepatic mass – likely left lateral liver lobe – and intraparenchymal lesion within the left lateral and right medial liver lobe
- Structural normal thorax, no evidence of pulmonary metastatic disease

SPECIES

Canine

INTERPRETATION OF THE FINDINGS & FURTHER RECOMMENDATIONS

The CT study is fitting the history of hepatic mass and regarding the history hepatocellular adenoma or carcinoma is the diagnosis. Complete surgical excision of the mass is considered feasible.

BREED

Border Collie

The intraparenchymal lesions in the left lateral liver lobe and the right medial liver lobe are concerning for metastasis.

SEX

Spayed Female

AGE

6 Years

INTERPRETED BY

Sebastian Schaub, DVM
Dr. med. vet. DipECVDI

HOSPITAL NAME

Mobile Pet Imaging

REFERRING VET

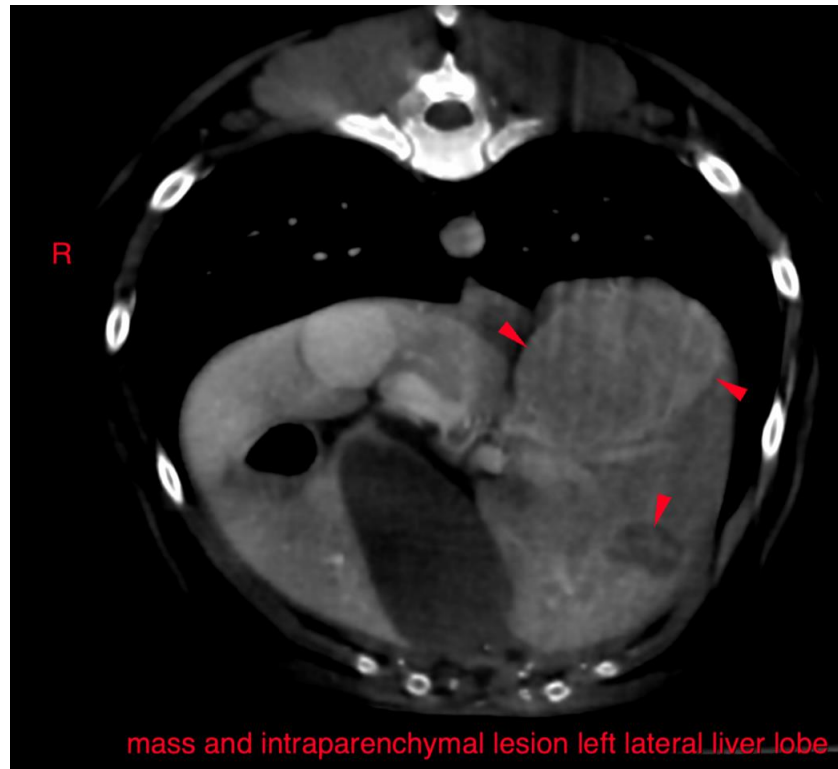
Meaux

INVOICE

56910

DATE

2-23-23





PATIENT

Molly Gutter

SPECIES

Canine

BREED

Border Collie

SEX

Spayed Female

AGE

6 Years

INTERPRETED BY

Sebastian Schaub, DVM
Dr. med. vet. DipECVDI

HOSPITAL NAME

Mobile Pet Imaging

REFERRING VET

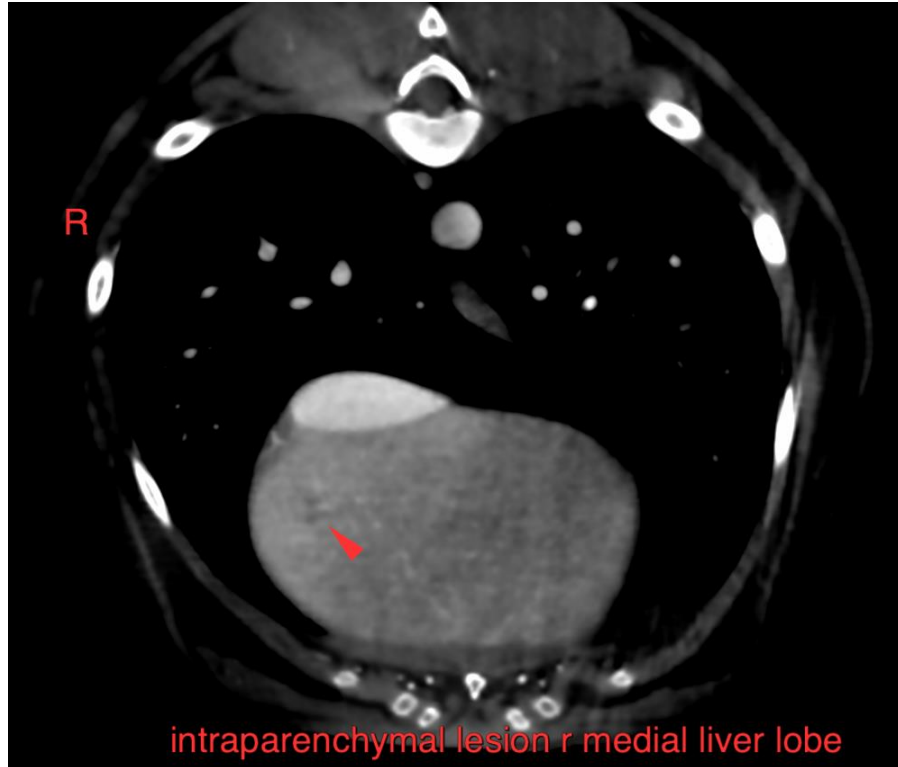
Meaux

INVOICE

56910

DATE

2-23-23



The information and recommendations provided are based on the images presented by the referring veterinarian/sonographer. No evaluation can be communicated regarding pathology that was not visible in the image/video clips provided.

Thank you for this referral. If the clinical or image interpretation does not parallel your findings or if I can be of any further assistance please contact me.

Sebastian Schaub, Sebastian Schaub, DVM, Dr. med. vet. DipECVDI
sebast.schaub@gmail.com