

**PATIENT**

Gotti Cruz

PRESENTING CLINICAL SIGNS

HX of RT epistaxis after patient hit his head at physical therapy

SPECIES

Canine

COMPUTED TOMOGRAPHY OF THE SKULL

A high resolution post-contrast CT study of the skull is provided for review.

BREEDAmerican Pitbull
Terrier**COMPUTED TOMOGRAPHIC FINDINGS**

Triadan 201 & 402 are absent, and the roots are remaining in the respective alveolar crests.

In the nasal cavity, a small amount of fluid attenuating material is attached to the nasal conchal & turbinate structures.

Both temporomandibular joints present congruent joint spaces with even subchondral bone surfaces and are considered within normal limits.

SEX

MN

Both tympanic bullae are aerated, the mucosal lining is not seen, the bony wall is smooth and thin. The external ear canals are within normal limits.

AGE

7 Years

The brain presents no deviation from normal anatomy and symmetry. The brain parenchyma is homogeneous and within normal limits for attenuation and distribution of contrast enhancement. The ventricular system is non-dilated and symmetric.

The submandibular and medial retropharyngeal lymph nodes are small and elongated with a normal short-to-long-axis-ratio is < 0.5, the attenuation and contrast enhancement pattern is uniform.

INTERPRETED BYSebastian Schaub, DVM
Dr. med. vet. DipECVDI

Multifocal spondylosis formation is seen along the cervical spine.

COMPUTED TOMOGRAPHIC DIAGNOSIS

- Small amount of exudate in nasal cavity
- Complicated dental fracture 201 and 402 without signs of root infection

HOSPITAL NAMEAnimal Surgical
Center**INTERPRETATION OF THE FINDINGS & FURTHER RECOMMENDATIONS**

The CT study presents without macromorphological abnormalities, explaining the epistaxis – given the history a traumatic origin is most likely.. The small amount of exudate in the nasal cavity are suggestive for remaining blood clots. If there are multiple episodes of epistaxis rule out other differentials such as immune mediated disease, non-specific rhinitis (e.g. lymphocytic plasmocytic), hyperviscosity syndrome (e.g. Leishmaniosis), other causes for coagulopathy or systemic hypertension.

REFERRING VETAquebogue
Veterinary Hospital**INVOICE**

56917

DATE

2-23-23



PATIENT

Gotti Cruz

SPECIES

Canine

BREED

American Pitbull
Terrier

SEX

MN

AGE

7 Years

INTERPRETED BY

Sebastian Schaub, DVM
Dr. med. vet. DipECVDI

HOSPITAL NAME

Animal Surgical
Center

REFERRING VET

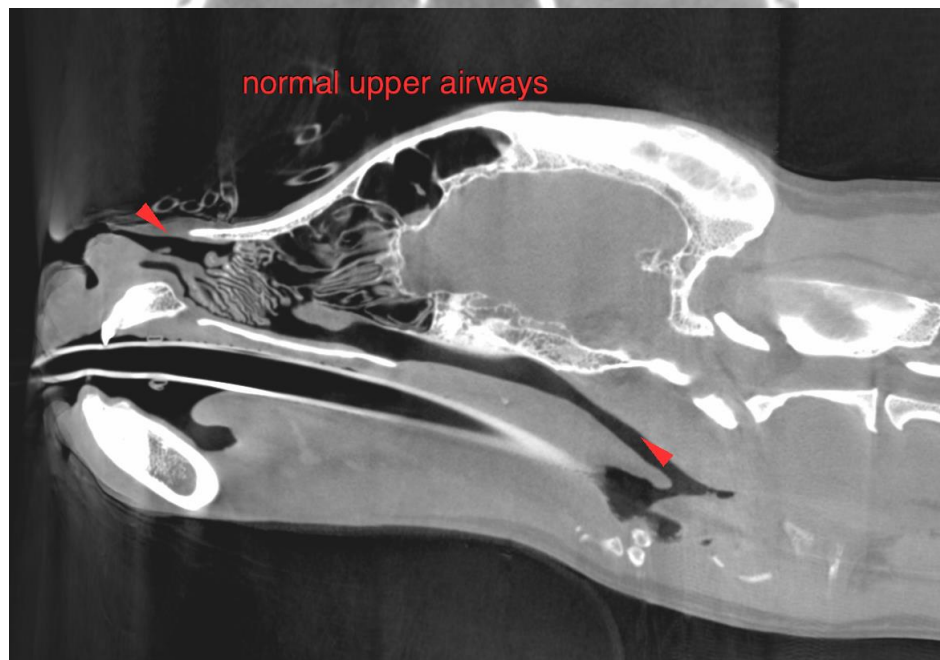
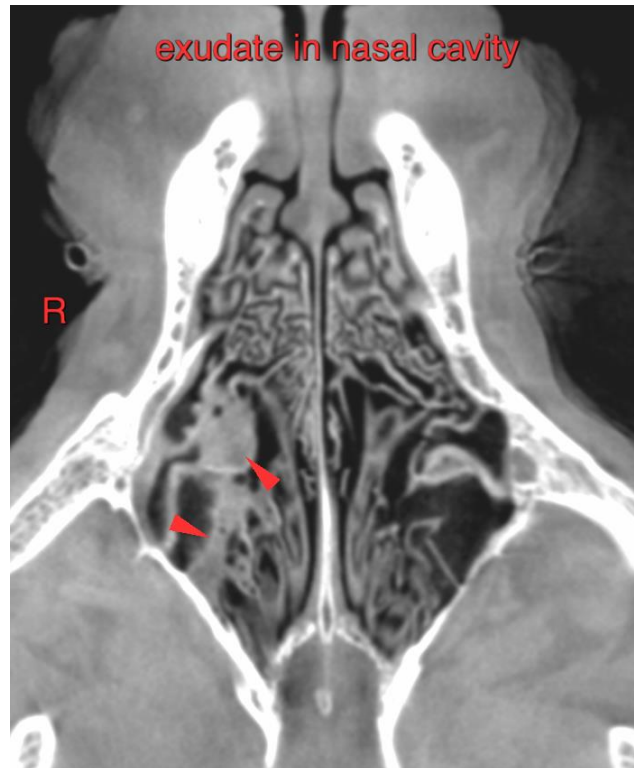Aquebogue
Veterinary Hospital

INVOICE

56917

DATE

2-23-23





PATIENT

Gotti Cruz

The information and recommendations provided are based on the images presented by the referring veterinarian/sonographer. No evaluation can be communicated regarding pathology that was not visible in the image/video clips provided.

SPECIES

Canine

Thank you for this referral. If the clinical or image interpretation does not parallel your findings or if I can be of any further assistance please contact me.

BREED

American Pitbull
Terrier

Sebastian Schaub, Sebastian Schaub, DVM, Dr. med. vet. DipECVDI
sebast.schaub@gmail.com

SEX

MN

AGE

7 Years

INTERPRETED BY

Sebastian Schaub, DVM
Dr. med. vet. DipECVDI

HOSPITAL NAME

Animal Surgical
Center

REFERRING VET

Aquebogue
Veterinary Hospital

INVOICE

56917

DATE

2-23-23