



PATIENT PRESENTING CLINICAL SIGNS

Lady Alaia Harris
SPECIES History: Acute onset of pyrexia temp 105 and generalized weakness on 2/16/22, noticed 2 cm nodular movable SQ mass ventral chin on 2/18/2022, and edema of upper lip and left side of face. Anesthesia, skull rads and aspirated mass on 2/19 clear fluid and bloody fluid on separate aspirates nondiagnostic cytology, unable to open mouth more than 1 cm on 2/19. became very swollen and edematous over entire ventral chin on 2/20. Persistent pyrexia despite Baytril and penicillin and meloxicam. able to open mouth today and visualize oral cavity, no obvious abnormalities. 2/2021 had retrobulbar abscess on right and zygomatic arch resection done to open and treat abscess.
Rabbit

BREED Abnormal PE/Chem/CBC/UA Results: initially on 2/16 increased WBC 13000, normal chemistry then on 2/19 decrease TP 4.2, albumin 2.4 and Hct 27% WBC 3400 after 3 days of SQ fluids
Flemish Giant

COMPUTED TOMOGRAPHIC STUDY OF THE SKULL

SEX A high plain CT study of the skull is provided for review.

Female

COMPUTED TOMOGRAPHIC FINDINGS

AGE Moderate to marked generalized swelling of the subcutaneous tissue along the ventral aspect of the skull – predominantly along the mandible bilaterally – is seen with multiple gas inclusions. The gas is extending dorsally with in the soft tissues of the buccal region bilaterally and left retrobulbar space. The rostral segment of the right zygomatic arch is absent – history of open management of retrobulbar abscess.
8 Years

INTERPRETED BY

Sebastian Schaub,
 DVM Dr. med. vet.
 DipECVDI

A small amount of gas is seen in the periapical periodontal space of triadan 208.

The nasal cavity presents the expected aerated spaces between thin & even conchae and turbinates with smooth mucosal lining.

HOSPITAL NAME

Aggie Animal Dental
 Cener

Both temporomandibular joints present congruent joint spaces with even subchondral bone surfaces and are considered within normal limits.

Both tympanic bullae are aerated, the mucosal lining is not seen, the bony wall is smooth and thin. The external ear canals are within normal limits.

REFERRING VET

Dr. Debra
 Scheenstra/Dr. Amy
 Fulton

COMPUTED TOMOGRAPHIC DIAGNOSIS

- Moderate to marked swelling along the mandible with extensive emphysema extending along the soft tissues of the buccal soft tissues up into the left retrobulbar space
- Mild periapical emphysema 208
- History of partial resection of the right zygomatic arch

INVOICE

14057

INTERPRETATION OF THE FINDINGS & FURTHER RECOMMENDATIONS

DATE

2/23/22



PATIENT Lady Alaia Harris

The CT study in combination with the clinical signs is highly suggestive for kind of gas phlegmon/gas gangrene due to gas forming bacteria within the soft tissues– possible preceding perforating wound (e.g. bite wound if there is a second rabbit) or laceration of the mucosa of the mouth. The gas is extending up into the right retrobulbar space and likely dissecting through the alveolar bone into the alveolar crest of triadan 108 – I do not see evidence of tooth root abscess or clinically relevant dental pathology. Check if there are superficial wounds.

SPECIES Rabbit

Extensive surgical debridement is considered as the therapy of choice. As anaerobic infection is considered likely, changing antimicrobial therapy to metronidazole might be beneficial.

BREED

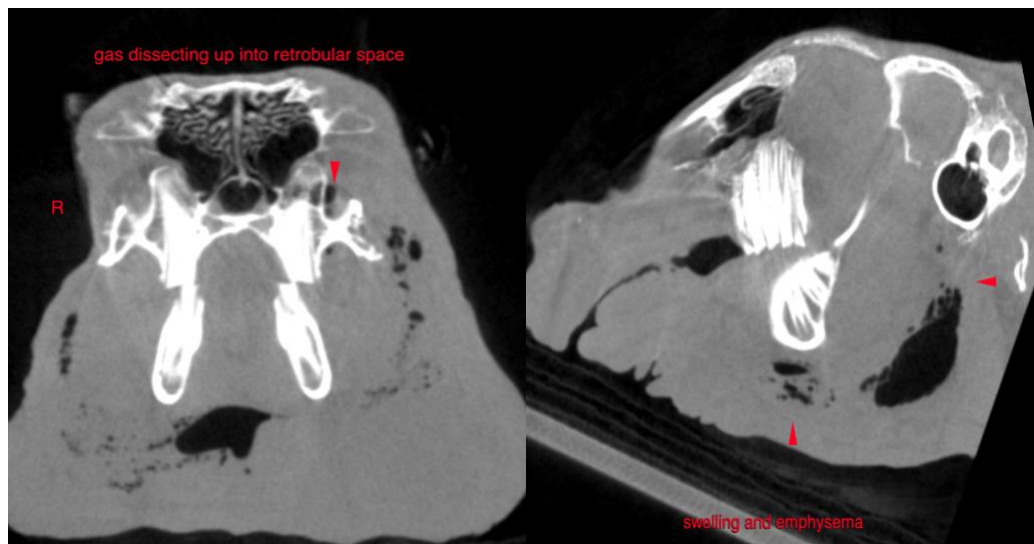
Flemish Giant

SEX

Female

AGE

8 Years



INTERPRETED BY

Sebastian Schaub,
DVM Dr. med. vet.
DipECVDI

The information and recommendations provided are based on the images presented by the referring veterinarian/sonographer. No evaluation can be communicated regarding pathology that was not visible in the image/video clips provided.

HOSPITAL NAME

Aggie Animal Dental
Cener

Thank you for this referral. If the clinical or image interpretation does not parallel your findings or if I can be of any further assistance please contact me.

REFERRING VET

Dr. Debra
Scheenstra/Dr. Amy
Fulton

Sebastian Schaub, Sebastian Schaub, DVM, Dr. med. vet. DipECVDI
sebast.schaub@gmail.com

INVOICE

14057

DATE

2/23/22