



**PATIENT**

Gandolf Jensen

**PRESENTING CLINICAL SIGNS**

General screening for an anesthetic for a lump removal on anus. Has a bilateral grade 2/6 heart murmur

**SPECIES**

Canine

**RADIOGRAPHIC STUDY OF THE THORAX**

Radiographs of the thorax in three imaging planes are provided for review.

**BREED**

Lhasa Apso

**RADIOGRAPHIC FINDINGS**

Moderate spondylosis formation is seen along the caudal thoracic spine.

**SEX**

MN

The heart is of normal size and shape, there is no evidence of cardiac chamber or vascular enlargement. The pulmonary vasculature is within normal limits.

**AGE**

12 Years, 9 Months

The cranial mediastinum presents the expected soft tissue opacity. The mediastinal width is less than twice the width of the vertebral column at the same level.

**INTERPRETED BY**

Sebastian Schaub, DVM  
Dr. med. vet. DipECVDI

The trachea is normal in diameter and presents the anticipated course. The luminal outline of the trachea is smooth.

The bronchial tree presents with thin walls and tapers uniformly towards the periphery as expected.

**HOSPITAL NAME**

Barry Magill

The lung parenchyma presents the expected architecture and opacity; the intrapulmonary vascular branching is seen up to the third order lung vessels.

The diaphragm is well delineated with even surface and the expected mild cranial bulging of the diaphragmatic cupola.

**RADIOGRAPHIC DIAGNOSIS**

**REFERRING VET**

Magill

- Subcutaneous lipoma dorsal to caudal thoracic spine
- No evidence of pulmonary metastatic spread

**INTERPRETATION OF THE FINDINGS & FURTHER RECOMMENDATIONS**

**INVOICE**

50508

The radiographic study of the thorax presents without significant abnormalities of the cardiovascular system. A cardiac echo can be used as advanced diagnostic test for further definition of cardiac chamber size and function.

**DATE**

2-23-22



**PATIENT**

Gandolf Jensen

**SPECIES**

Canine

**BREED**

Lhasa Apso

**SEX**

MN

**AGE**

12 Years, 9 Months

**INTERPRETED BY**

Sebastian Schaub, DVM  
Dr. med. vet. DipECVDI

**HOSPITAL NAME**

Barry Magill

**REFERRING VET**

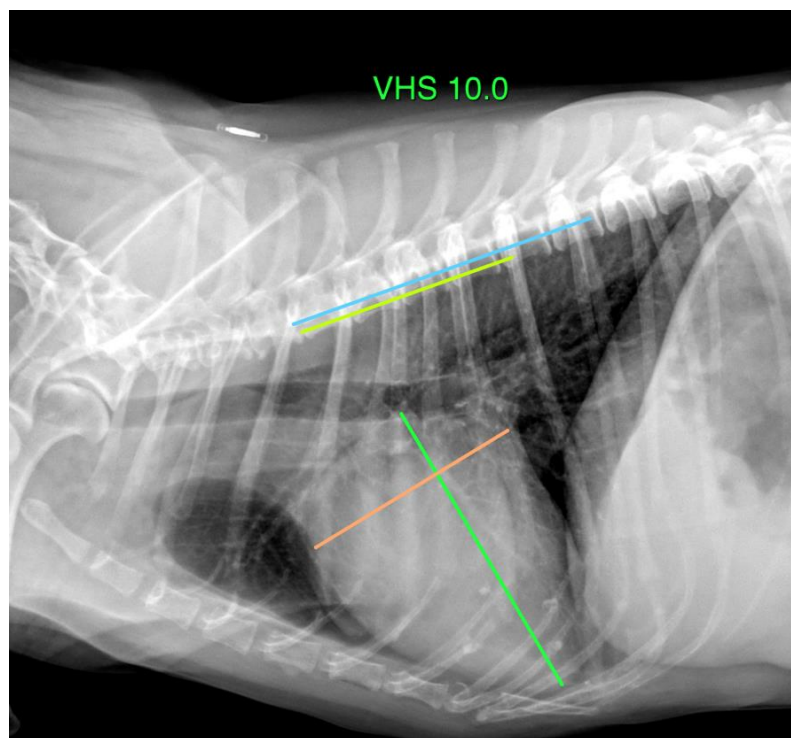
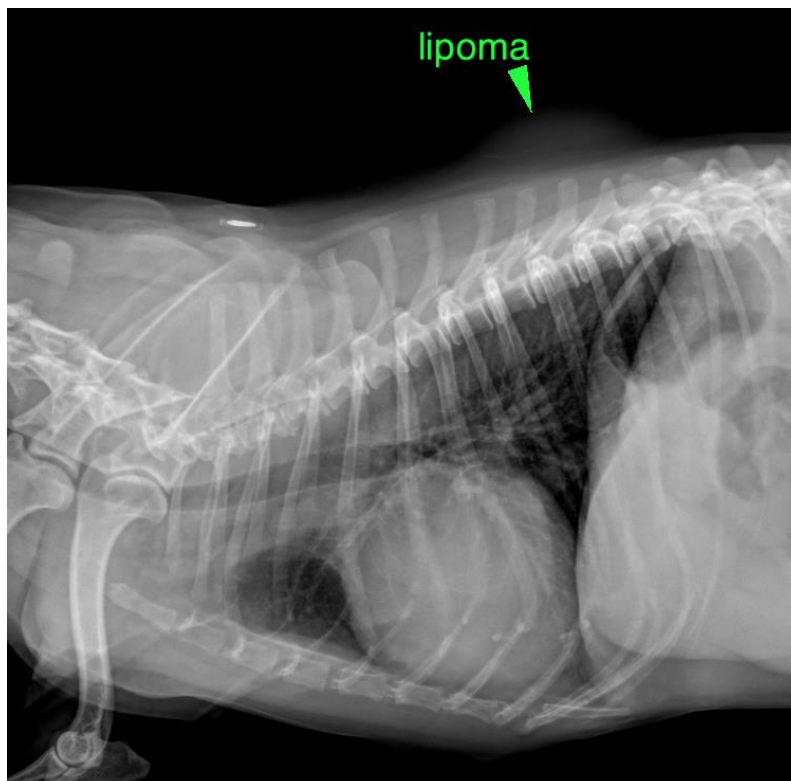
Magill

**INVOICE**

50508

**DATE**

2-23-22





**PATIENT**

Gandolf Jensen

**SPECIES**

Canine

**BREED**

Lhasa Apso

**SEX**

MN

**AGE**

12 Years, 9 Months

**INTERPRETED BY**

Sebastian Schaub, DVM  
Dr. med. vet. DipECVDI

**HOSPITAL NAME**

Barry Magill

**REFERRING VET**

Magill

**INVOICE**

50508

**DATE**

2-23-22

The information and recommendations provided are based on the images presented by the referring veterinarian/sonographer. No evaluation can be communicated regarding pathology that was not visible in the image/video clips provided.

Thank you for this referral. If the clinical or image interpretation does not parallel your findings or if I can be of any further assistance please contact me.

**Sebastian Schaub**, Sebastian Schaub, DVM, Dr. med. vet. DipECVDI  
sebast.schaub@gmail.com