



**PATIENT**

Rowley Henderson

**SPECIES**

Canine

**BREED**

Doberman Mix

**SEX**

MN

**AGE**

5 Years

**INTERPRETED BY**

Sebastian Schaub, DVM  
Dr. med. vet. DipECVDI

**HOSPITAL NAME**

Northshore  
Veterinary Hospital

**REFERRING VET**

Kristin Williams

**INVOICE**

56887

**DATE**

2-22-23

**PRESENTING CLINICAL SIGNS**

Non-weight bearing lameness on right rear after playing too hard with his friend on 2/17. By exam on 2/18 it was a partial weight bearing lameness. Has improved with carprofen, gabapentin, trazodone and rest, but still reluctant to put much weight on the leg.

Abnormal PE/Chem/CBC/UA Results: Right stifle soft tissue swelling. Joint effusion appreciable on 2/18, but has reduced. Can not get any tibial thrust or drawer motion, even under sedation. Suspect partial ACL tear.

**RADIOGRAPHIC STUDY OF THE STIFLE JOINTS**

Radiographs of the stifle joints in two orthogonal imaging planes are provided for review.

**RADIOGRAPHIC FINDINGS**

The periarticular bones of the right stifle joint present moderate osteophyte new bone formation and a moderate intracapsular soft tissue swelling is seen.

The periarticular bones of the left stifle joint have smooth osseous margins. The left stifle joint presents a mild increased volume of the intraarticular soft tissue shadow.

**RADIOGRAPHIC DIAGNOSIS**

- Moderate degenerative osteoarthritis right stifle joint
- Moderate articular swelling right stifle joint
- Mild articular swelling left stifle joint

**INTERPRETATION OF THE FINDINGS & FURTHER RECOMMENDATIONS**

The radiographic study is consistent with chronic degenerative osteoarthritis with concomitant joint effusion of the right stifle joint. The most-likely underlying cause is (partial) rupture of the cranial cruciate ligament with or without meniscal disease. The mild effusion of the left stifle joint might indicate early stage of degenerative joint disease as well.



**PATIENT**

Rowley Henderson

**SPECIES**

Canine

**BREED**

Doberman Mix

**SEX**

MN

**AGE**

5 Years

**INTERPRETED BY**

Sebastian Schaub, DVM  
Dr. med. vet. DipECVDI

**HOSPITAL NAME**

Northshore  
Veterinary Hospital

**REFERRING VET**

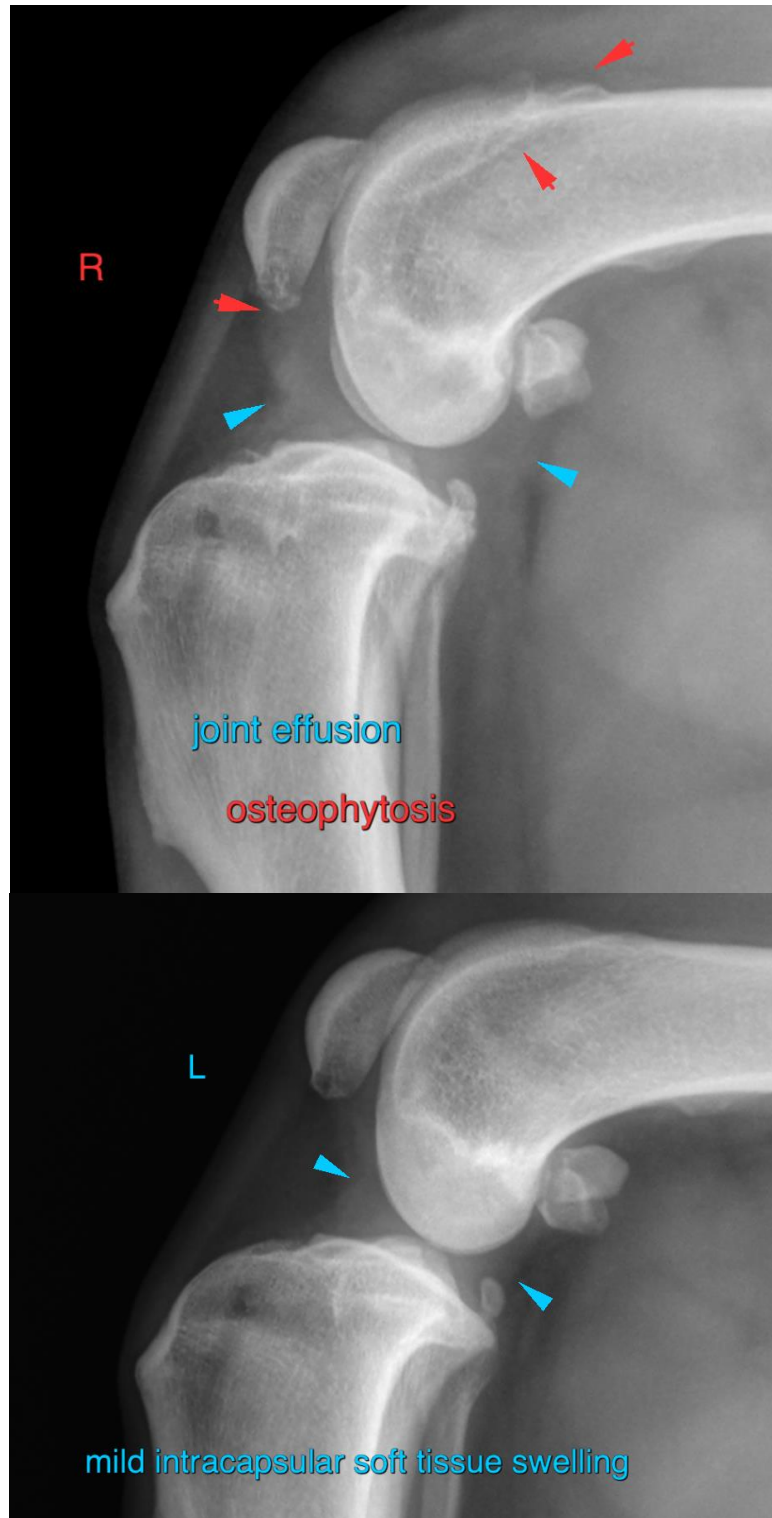
Kristin Williams

**INVOICE**

56887

**DATE**

2-22-23





**PATIENT**

Rowley Henderson

**SPECIES**

Canine

The information and recommendations provided are based on the images presented by the referring veterinarian/sonographer. No evaluation can be communicated regarding pathology that was not visible in the image/video clips provided.

**BREED**

Doberman Mix

Thank you for this referral. If the clinical or image interpretation does not parallel your findings or if I can be of any further assistance please contact me.

**Sebastian Schaub**, Sebastian Schaub, DVM, Dr. med. vet. DipECVDI  
sebast.schaub@gmail.com

**SEX**

MN

**AGE**

5 Years

**INTERPRETED BY**

Sebastian Schaub, DVM  
Dr. med. vet. DipECVDI

**HOSPITAL NAME**

Northshore  
Veterinary Hospital

**REFERRING VET**

Kristin Williams

**INVOICE**

56887

**DATE**

2-22-23