



PATIENT

Layla Mosier

PRESENTING CLINICAL SIGNS

Limping LF for a couple months mildy and within the past two weeks has gotten worse. No known injuries.

Abnormal PE/Chem/CBC/UA Results: Limping L front limb; carpus has decreased range-of-motion with flexion and is thickened

SPECIES

Canine

RADIOGRAPHIC STUDY OF THE FRONT LIMBS

A complete set of radiographs of the front limbs is provided for review.

BREED

Boxer Mix

RADIOGRAPHIC FINDINGS

Both shoulder joints present smooth osseous margins and the surrounding soft tissue structures are within normal limits.

SEX

Spayed

The periarticular bones of both elbow joints present moderate osteophyte new bone formation. The contour of the medial coronoid process of the elbow joints has a ill-defined tip.

The periarticular bones of the carpal joints bilaterally present moderate osteophyte new bone formation, L>R. The surrounding soft tissue structures are within normal limits.

AGE

9 Years, 11 Months

RADIOGRAPHIC DIAGNOSIS

- Coronoid disease elbow joints bilaterally
- Degenerative osteoarthritis elbow joints bilaterally
- Degenerative osteoarthritis carpal joints bilaterally, L>R
- Normal shoulder joints

INTERPRETED BY

Sebastian Schaub, DVM
Dr. med. vet. DipECVDI

INTERPRETATION OF THE FINDINGS & FURTHER RECOMMENDATIONS

The radiographic study of the front limbs presents signs of degenerative joint disease of the elbow and carpal joints of both front limbs. The findings may contribute to the clinically appreciated left front limb lameness – acute on chronic insult may have caused deterioration of clinical signs.

HOSPITAL NAME

Elizabeth Animal Hospital

REFERRING VET

Jennifer Redus, DVM

INVOICE

56888

DATE

2-22-23



PATIENT

Layla Mosier

SPECIES

Canine

BREED

Boxer Mix

SEX

Spayed

AGE

9 Years, 11 Months

INTERPRETED BY

Sebastian Schaub, DVM
Dr. med. vet. DipECVDI

HOSPITAL NAME

Elizabeth Animal
Hospital

REFERRING VET

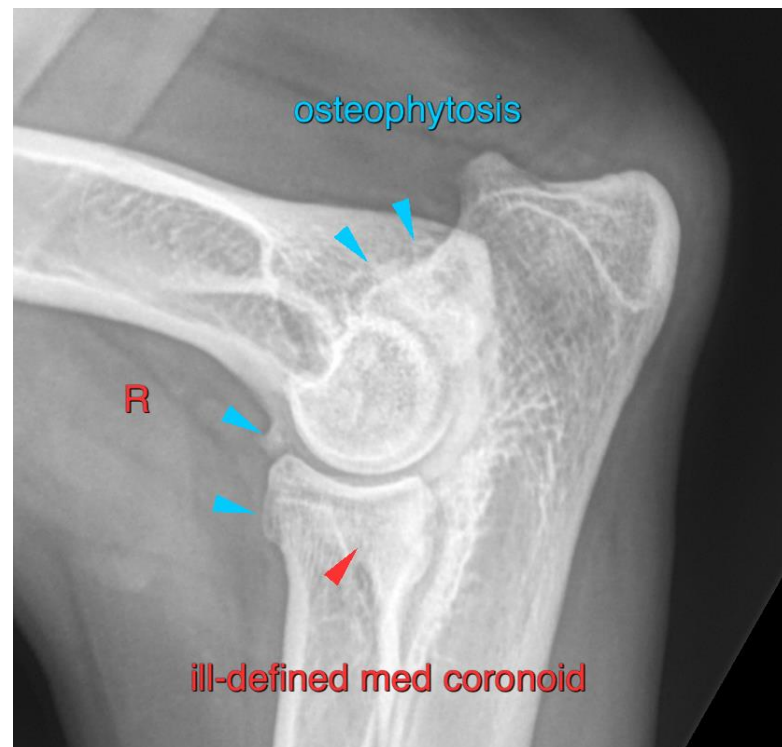
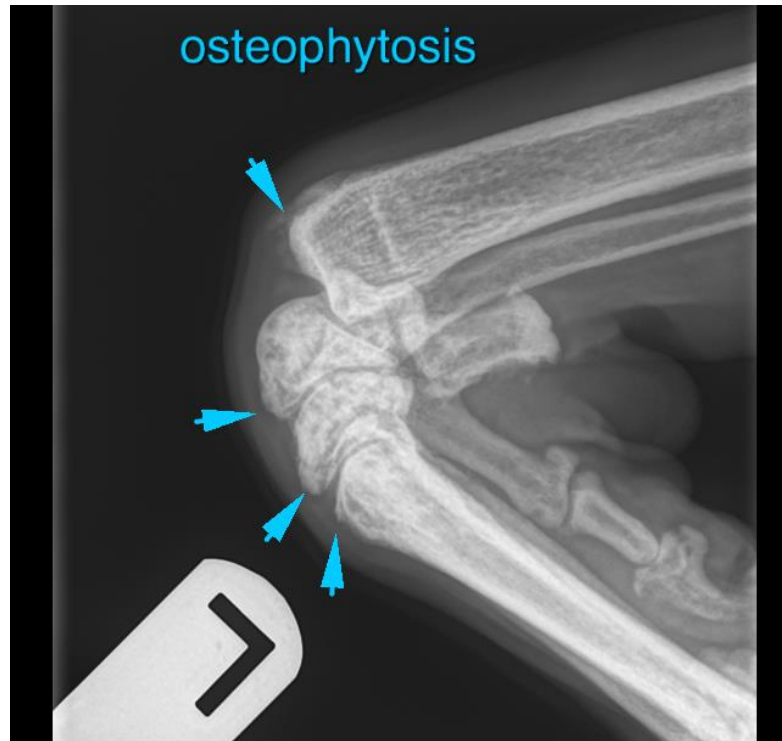Jennifer Redus, DVM

INVOICE

56888

DATE

2-22-23





PATIENT

Layla Mosier

SPECIES

Canine

BREED

Boxer Mix

SEX

Spayed

AGE

9 Years, 11 Months

INTERPRETED BY

Sebastian Schaub, DVM
Dr. med. vet. DipECVDI

HOSPITAL NAME

Elizabeth Animal
Hospital

REFERRING VET

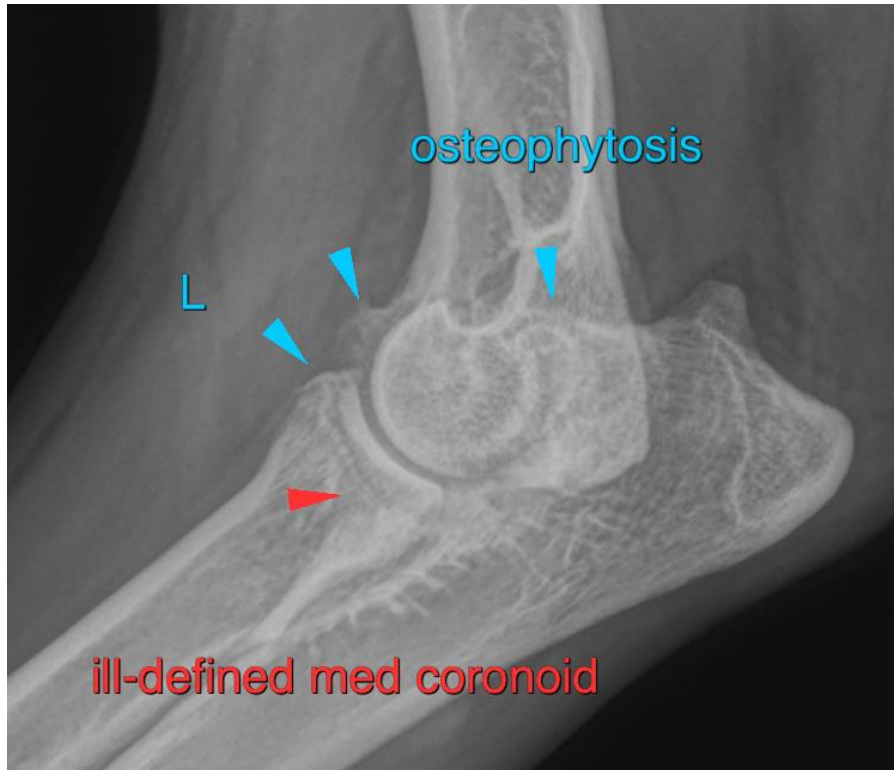
Jennifer Redus, DVM

INVOICE

56888

DATE

2-22-23



The information and recommendations provided are based on the images presented by the referring veterinarian/sonographer. No evaluation can be communicated regarding pathology that was not visible in the image/video clips provided.

Thank you for this referral. If the clinical or image interpretation does not parallel your findings or if I can be of any further assistance please contact me.

Sebastian Schaub, Sebastian Schaub, DVM, Dr. med. vet. DipECVDI
sebast.schaub@gmail.com