



PATIENT PRESENTING CLINICAL SIGNS

Thor Horton Patient presented for stiff gait on right pelvic limb, nonpainful on extension and flexion. When at a trot throws right stifle out laterally. Unable to elicit drawer.

SPECIES RADIOGRAPHIC STUDY OF THE PELVIS AND STIFLE JOINTS

Canine Radiographs of the pelvis in a VD view and radiographs of the stifle joints in two orthogonal imaging planes are provided for review.

BREED RADIOGRAPHIC FINDINGS

Pitbull Terrier The right acetabular groove is misshapen, and the medial osseous margin cannot be clearly delineated and is mildly irregular in comparison to the contralateral side. The right femoral head is located deep within the right acetabular groove. Despite the symmetric positioning the right obturator foramen is significantly narrowed.

SEX

MN The stifle joints present smooth osseous margins, there is a mild increased intracapsular soft tissue swelling of both stifle joints.

AGE

3.75 Years

- Suspect history of right acetabular fracture and fracture of the right ischial bone
- Equivocal articular swelling of the stifle joints bilaterally

INTERPRETED BY

Sebastian Schaub, DVM
Dr. med. vet. DipECVDI

INTERPRETATION OF THE FINDINGS & FURTHER RECOMMENDATIONS

The asymmetry of the acetabular groove with the malformed right acetabular groove and misshapen right obturator foramen are highly suggestive for chronic acetabular/pelvic fracture – check for history of potential trauma earlier in life. The finding is a potential explanation for the abnormal gait. A faux-profile projection (lateral view of the hip joint) of the right & left hemipelvis or CT study can be used to confirm the diagnosis. A potential is marked tilting of the pelvis, causing the abnormal appearance of the right coxofemoral joint, but the iliac wings are symmetric.

HOSPITAL NAME

Boca Park Animal Hospital

The mild intracapsular soft tissue swelling of the stifle joints is bilaterally symmetric and considered as a normal amount of synovial fluid.

REFERRING VET

Dr. Corinna Gorgon

INVOICE

50477

DATE

2-22-22



PATIENT

Thor Horton

SPECIES

Canine

BREED

Pitbull Terrier

SEX

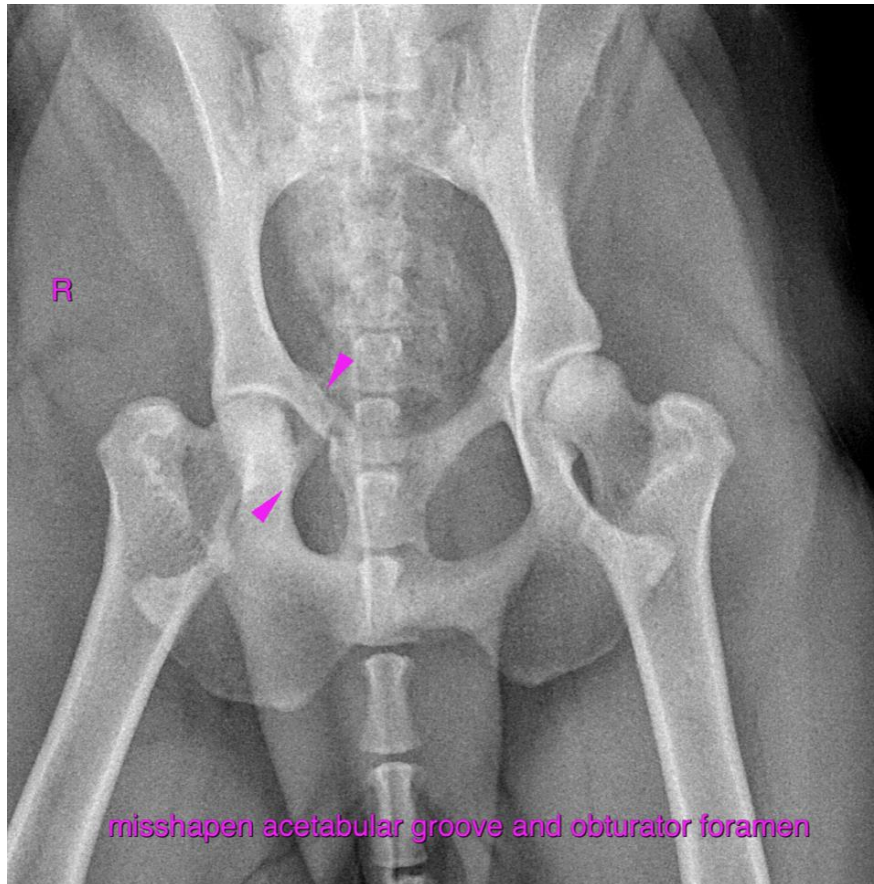
MN

AGE

3.75 Years

INTERPRETED BY

Sebastian Schaub, DVM
Dr. med. vet. DipECVDI



HOSPITAL NAME

Boca Park Animal
Hospital

REFERRING VET

Dr. Corinna Gorgon

INVOICE

50477

DATE

2-22-22

The information and recommendations provided are based on the images presented by the referring veterinarian/sonographer. No evaluation can be communicated regarding pathology that was not visible in the image/video clips provided.

Thank you for this referral. If the clinical or image interpretation does not parallel your findings or if I can be of any further assistance please contact me.

Sebastian Schaub, Sebastian Schaub, DVM, Dr. med. vet. DipECVDI
sebast.schaub@gmail.com