



PATIENT

Dash Robbins

PRESENTING CLINICAL SIGNS

Patient presented for baseline radiographs of chest- has history of feline asthma for which he is being managed on prednisone. Patient had a flare up a few weeks ago when owner was trying to decrease prednisone dose. Currently at 2.5mg PO SID. Owner also has inhaler at home (flovent at 110mg)

SPECIES

Feline

RADIOGRAPHIC STUDY OF THE THORAX

Radiographs of the thorax in three imaging planes are provided for review.

BREED

Tuxedo

RADIOGRAPHIC FINDINGS

The thorax has a mild barrel chested conformation, best appreciated in the VD projection with widening of the intercostal spaces.

SEX

The surrounding bony structures are within normal limits.

MN

The extrathoracic soft tissues present homogeneous without abnormalities.

AGE

3 Years

The heart is of normal size and shape, there is no evidence of cardiac chamber or vascular enlargement. The pulmonary vasculature is within normal limits.

INTERPRETED BY

Sebastian Schaub, DVM
Dr. med. vet. DipECVDI

The trachea is normal in diameter and presents the anticipated course. The luminal outline of the trachea is smooth.

A mild bronchial lung pattern is present.

The lung parenchyma presents the expected architecture and opacity; the intrapulmonary vascular branching is seen up to the third order lung vessels.

HOSPITAL NAME

Boca Park Animal
Hospital

The diaphragm is well delineated with even surface and the expected mild cranial bulging of the diaphragmatic cupola.

RADIOGRAPHIC DIAGNOSIS

REFERRING VET

Dr. Corinna Gorgon

- Mild overinflation of the lung
- Very mild bronchial lung pattern

INTERPRETATION OF THE FINDINGS & FURTHER RECOMMENDATIONS

INVOICE

50474

The radiographic changes are consistent with the history of feline bronchial disease ('feline asthma'). The diverging ribs are indicating mild hyperinflation of the lung. There are no signs for active pneumonia.

DATE

2-22-22



PATIENT

Dash Robbins

SPECIES

Feline

BREED

Tuxedo

SEX

MN

AGE

3 Years

INTERPRETED BY

Sebastian Schaub, DVM
Dr. med. vet. DipECVDI

HOSPITAL NAME

Boca Park Animal
Hospital

REFERRING VET

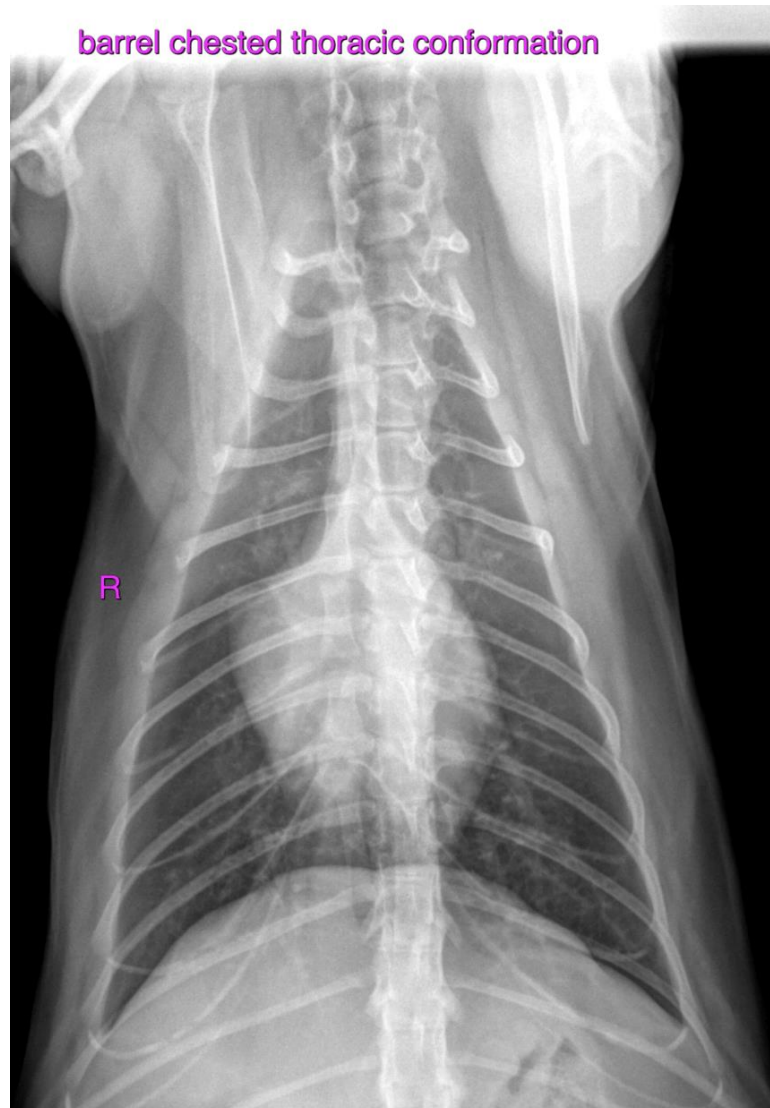
Dr. Corinna Gorgon

INVOICE

50474

DATE

2-22-22



The information and recommendations provided are based on the images presented by the referring veterinarian/sonographer. No evaluation can be communicated regarding pathology that was not visible in the image/video clips provided.

Thank you for this referral. If the clinical or image interpretation does not parallel your findings or if I can be of any further assistance please contact me.

Sebastian Schaub, Sebastian Schaub, DVM, Dr. med. vet. DipECVDI
sebast.schaub@gmail.com