

**PATIENT**

Darby Zilch

**PRESENTING CLINICAL SIGNS**

swollen carpi after medication trial

**SPECIES**

Canine

**RADIOGRAPHIC STUDY OF THE CARPAL JOINTS**

Radiographs of the carpal joints in two orthogonal imaging planes are provided for review.

**BREED**

Weimaraner

Both carpal joints present a moderate periarticular soft tissue swelling, L&gt;R.

There is palmar subluxation of the left middle carpal joint. The periarticular bones of the left carpal joint present mild osteophyte new bone formation.

**SEX**

SF

**RADIOGRAPHIC DIAGNOSIS**

- Bilateral moderate to marked articular swelling of the carpal joints
- Left sided carpal instability middle carpal joint
- Mild degenerative osteoarthritis left carpal joint

**AGE**

6

**INTERPRETED BY**Sebastian Schaub, DVM  
Dr. med. vet. DipECVDI**INTERPRETATION OF THE FINDINGS & FURTHER RECOMMENDATIONS**

Given the bilateral swelling of the carpal joints, immune mediated non-erosive polyarthritis or less likely infectious arthritis is a potential here with secondary instability of the left carpal joint. If there is a history of preceding trauma ('high-rise' syndrome) carpal hyperextension syndrome with laceration of the palmar fibrocartilaginous plate of the joint capsule is a potential as well. If not done so yet, recommend tapping the carpal joints as well as stressed radiographs under general anesthesia are recommended.

**HOSPITAL NAME**Yorkville Animal  
Hospital**REFERRING VET**

Dr. Long

**INVOICE**

50468

**DATE**

2-22-22



**PATIENT**

Darby Zilch

**SPECIES**

Canine

**BREED**

Weimaraner

**SEX**

SF

**AGE**

6

**INTERPRETED BY**

Sebastian Schaub, DVM  
Dr. med. vet. DipECVDI

**HOSPITAL NAME**

Yorkville Animal  
Hospital

**REFERRING VET**

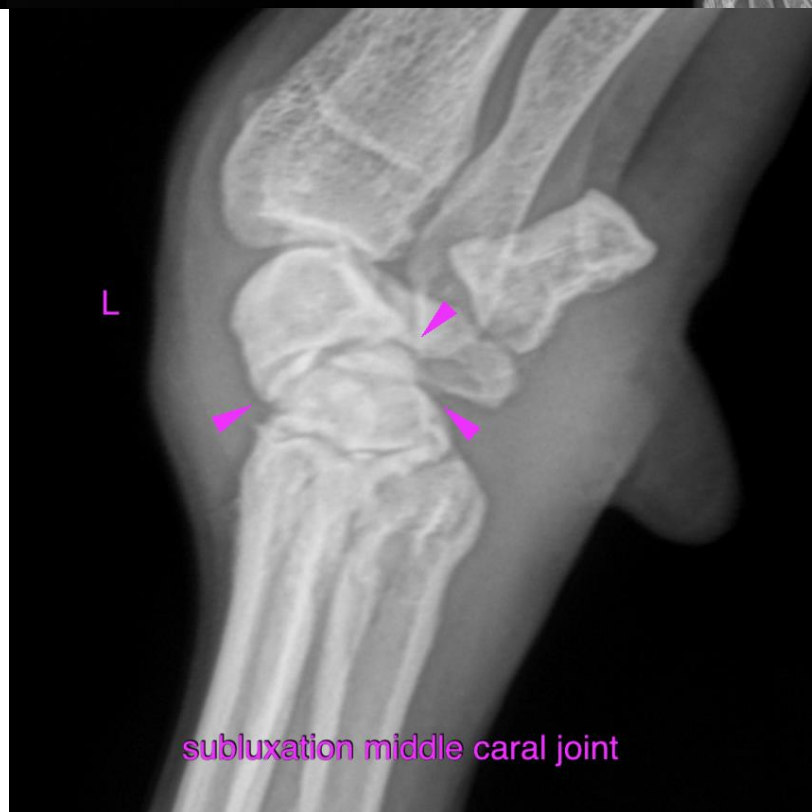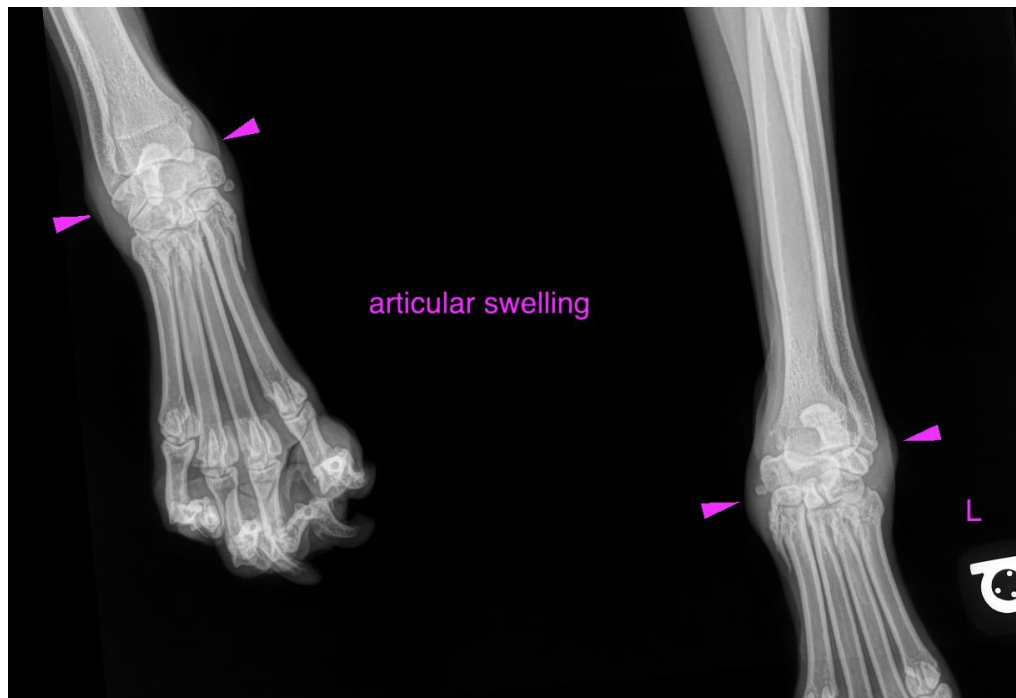
Dr. Long

**INVOICE**

50468

**DATE**

2-22-22





**PATIENT**

Darby Zilch

**SPECIES**

Canine

The information and recommendations provided are based on the images presented by the referring veterinarian/sonographer. No evaluation can be communicated regarding pathology that was not visible in the image/video clips provided.

**BREED**

Weimaraner

Thank you for this referral. If the clinical or image interpretation does not parallel your findings or if I can be of any further assistance please contact me.

**Sebastian Schaub**, Sebastian Schaub, DVM, Dr. med. vet. DipECVDI  
sebast.schaub@gmail.com

**SEX**

SF

**AGE**

6

**INTERPRETED BY**

Sebastian Schaub, DVM  
Dr. med. vet. DipECVDI

**HOSPITAL NAME**

Yorkville Animal  
Hospital

**REFERRING VET**

Dr. Long

**INVOICE**

50468

**DATE**

2-22-22