



PATIENT

Bear Bartels

PRESENTING CLINICAL SIGNS

Owner reports Bear's littermate and father both died of systemic cancer. Bear is doing well at home.
Abnormal PE/Chem/CBC/UA Results: NSF

SPECIES

Canine

COMPUTED TOMOGRAPHY OF THE THORAX AND ABDOMEN

A high resolution pre- and post-contrast CT study of the abdomen and a plain CT study of the thorax are provided for review.

BREED

German Shepherd

COMPUTED TOMOGRAPHIC FINDINGS

Thorax

Multifocal spondylosis formation is seen along the thoracic spine. The costal cartilages present advanced degenerative changes. Multiple intervertebral discs along the thoracic spine are bulging into the vertebral canal, occupying up to 10% of the cross-sectional area of the vertebral canal and distorting the ventral epidural space.

SEX

Male Neutered

Granular mineralization is seen at the cranial aspect of the major tubercle of the right humerus, level with the insertion of the supraspinatus tendon.

AGE

11 Years

The sternal, cranial mediastinal and tracheobronchial lymph nodes are small elongated with a normal short-to-long-axis-ratio is < 0.5, the attenuation pattern is uniform.

INTERPRETED BY

Sebastian Schaub, DVM
Dr. med. vet. DipECVDI

The cardiovascular structures including the pulmonary vasculature are within normal limits.

The bronchial tree presents with regular branching and tapers uniformly towards the periphery as expected, the bronchial walls are thin and smooth. The bronchus-to-artery ratio is within normal limits.

HOSPITAL NAME

Catskill Veterinary Services, PLLC

The dorsal dependent aspects of the lung parenchyma present zones with mild dystelectasis. Randomly distributed punctate mineralization of the lung parenchyma is appreciated.

Small incidental gas pockets are seen within the esophageal lumen, there is no evidence of abnormal dilation.

Abdomen

REFERRING VET

Dr. Joseph D'Abbraccio

The serosal fat presents normal attenuation behavior. There is no evidence of peritoneal effusion or peritonitis.

Both kidneys present within normal limits for size, shape and organ architecture. After contrast administration in the cranial aspect of the left kidney, a well-defined, roundish parenchymal filling defect measuring 16 mm in diameter is seen.

INVOICE

56877

The adrenal glands are within normal limits for size, shape and organ architecture.

Both liver and spleen present with normal shape, even surface, uniformly attenuating parenchyma and homogeneous contrast enhancement, unremarkable.

DATE

2-21-23

The portal vein presents a normal order of its tributary veins and intrahepatic branching. No abnormal vessel is noted inside and outside of the liver parenchyma.



PATIENT

Bear Bartels

The pancreas is evenly contoured, the pancreatic parenchyma is homogeneous and presents uniform contrast enhancement.

The position, delineation, wall and content of the gastrointestinal tract are considered within normal limits throughout.

SPECIES

Canine

Multifocal spondylosis formation is seen along the lumbar spine. Level with the intervertebral disc space L6/L7 mineralized disc material is bulging into the vertebral canal, occupying approximately 50% of the cross-sectional area of the vertebral canal at the same level – the cauda equina fibers at the same level are deviated dorsally. The intervertebral disc L5/L6 is protruding into the vertebral canal, occupying approximately 15% of the cross-sectional area of the vertebral canal.

BREED

German Shepherd

Both coxofemoral joints present moderate osteophyte new bone formation.

COMPUTED TOMOGRAPHIC DIAGNOSIS

SEX

Male Neutered

- Chronic intervertebral disc protrusion L6/L7 with compression of the cauda equina fibers
- Multifocal intervertebral disc protrusion along the thoracic spine and level L5/L6 with possible dynamic myelocompression
- Renal cortical cyst
- Pulmonary osteomas
- Degenerative osteoarthritis coxofemoral joints bilaterally
- Advanced degenerative changes along the costal cartilages
- Calcifying tendinopathy right supraspinatus tendon
- Spondylosis deformans

AGE

11 Years

INTERPRETED BY

Sebastian Schaub, DVM
Dr. med. vet. DipECVDI

INTERPRETATION OF THE FINDINGS & FURTHER RECOMMENDATIONS

The CT study presents multiple advanced degenerative changes along the axial and appendicular skeleton.

HOSPITAL NAME

Catskill Veterinary
Services, PLLC

There is no sign for neoplastic disease.

REFERRING VET

Dr. Joseph
D'Abbraccio

INVOICE

56877

DATE

2-21-23



PATIENT

Bear Bartels

SPECIES

Canine

BREED

German Shepherd

SEX

Male Neutered

AGE

11 Years

INTERPRETED BY

Sebastian Schaub, DVM
Dr. med. vet. DipECVDI

HOSPITAL NAME

Catskill Veterinary
Services, PLLC

REFERRING VET

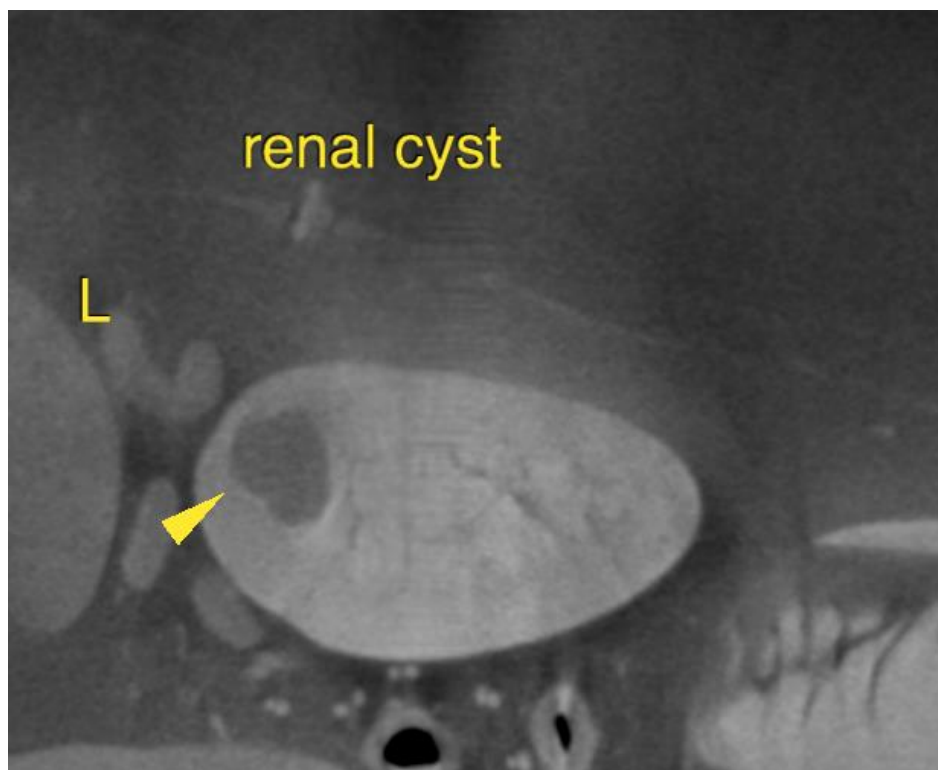
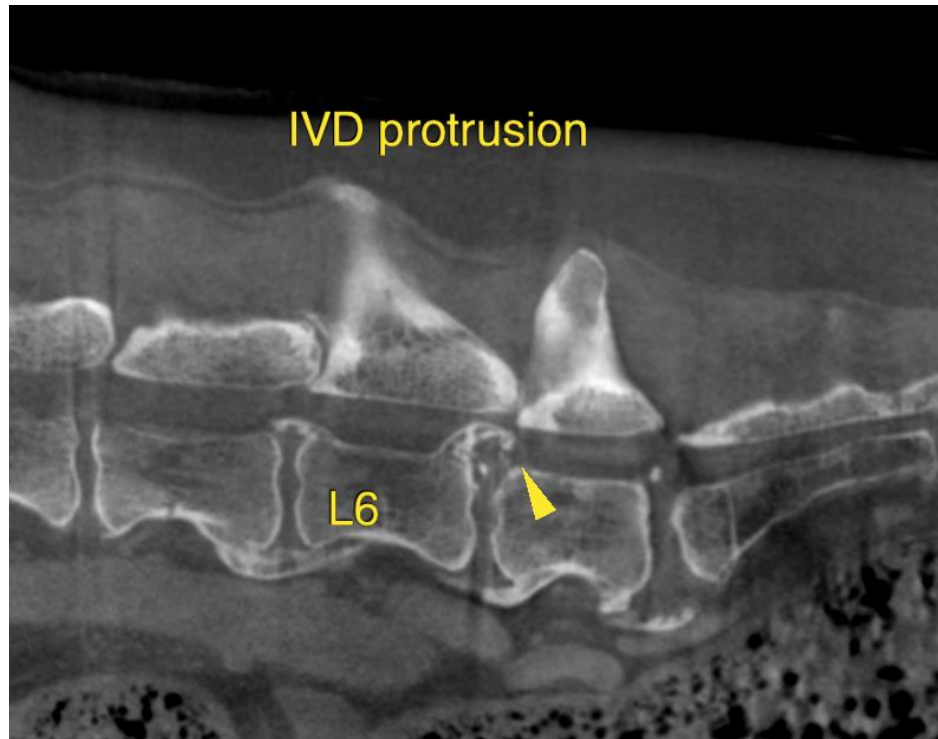
Dr. Joseph
D'Abbraccio

INVOICE

56877

DATE

2-21-23





PATIENT

Bear Bartels

SPECIES

Canine

BREED

German Shepherd

SEX

Male Neutered

AGE

11 Years

INTERPRETED BY

Sebastian Schaub, DVM
Dr. med. vet. DipECVDI

HOSPITAL NAME

Catskill Veterinary
Services, PLLC

REFERRING VET

Dr. Joseph
D'Abbraccio

INVOICE

56877

DATE

2-21-23

The information and recommendations provided are based on the images presented by the referring veterinarian/sonographer. No evaluation can be communicated regarding pathology that was not visible in the image/video clips provided.

Thank you for this referral. If the clinical or image interpretation does not parallel your findings or if I can be of any further assistance please contact me.

Sebastian Schaub, Sebastian Schaub, DVM, Dr. med. vet. DipECVDI
sebast.schaub@gmail.com