



PATIENT PRESENTING CLINICAL SIGNS

Ziva Benton
SPECIES Canine
BREED Pit Bull Terrier

Orbital disease OD -Has a history of Addison's disease (owner is LVT) -Eye exam on 10/7/21 showed signs of Horner's syndrome along with lateral strabismus OD. Went to see neurologist and had MRI done at that time, confirmed suspicion for atypical idiopathic Horner's syndrome. - Presented again to us on 2/17/22 with severe acute orbital cellulitis OD. Improved but did not resolve with oral/topical anti-inflammatory treatment. Orbital ultrasound showed hypoechoic areas retrobulbar and FNA was obtained from ventral area of conjunctival swelling and submitted for cytology. Referred for CT scan (due to unusual history and orbital swelling OD).

COMPUTED TOMOGRAPHY OF THE SKULL

A high resolution pre- and post-contrast CT study of the skull is provided for review.

COMPUTED TOMOGRAPHIC FINDINGS

SEX FS
AGE 5

The tooth elements 104, 105 and 207 are absent.

The nasal cavity presents the expected aerated spaces between thin & even conchae and turbinates with smooth mucosal lining.

A moderate soft swelling is seen in the right retrobulbar space, following the course of the extraocular muscles – extending caudally up to the region of the optic canal. The right optic canal is moderately widened and the right aspect of the presphenoid bone and the right ala of the basisphenoid bone present local extensive permeative osteolytic lesions with perforation of the cranial fossa. Post contrast administration, no increased contrast enhancement pattern of the mass is appreciated.

Both temporomandibular joints present congruent joint spaces with even subchondral bone surfaces and are considered within normal limits.

Both tympanic bullae are aerated, the mucosal lining is not seen, the bony wall is smooth and thin. The external ear canals are within normal limits.

The brain presents no deviation from normal anatomy and symmetry. The brain parenchyma is homogeneous and within normal limits for attenuation and distribution of contrast enhancement. The ventricular system is non-dilated and symmetric.

The submandibular and medial retropharyngeal lymph nodes are small and elongated with a normal short-to-long-axis-ratio is < 0.5, the attenuation and contrast enhancement pattern is uniform.

COMPUTED TOMOGRAPHIC DIAGNOSIS

- Right sided retrobulbar mass with monostotic aggressive osteolytic lesions of the sphenoid bone
- Multiple absent teeth, see above

INTERPRETATION OF THE FINDINGS & FURTHER RECOMMENDATIONS

The findings are consistent with a biologically aggressive soft tissue mass in the region of the right optic canal/caudal aspect of the right retrobulbar space. Neoplasia – such as optic nerve

INTERPRETED BY

Sebastian Schaub, DVM
 Dr. med. vet. DipECVDI

HOSPITAL NAME

Advanced Animal
 Imaging

REFERRING VET

Blair Hollowell, DVM

INVOICE

50467

DATE

2-21-22



PATIENT

Ziva Benton

meningioma, fibrosarcoma, chondrosarcoma, melanoma, carcinoma, round cell tumor – is the top differential. Inflammatory origin is a consideration as well, such as inflammatory pseudotumor mimicking biologically aggressive neoplasm or (mycotic) granuloma. Further definition would warrant FNA sampling ± biopsy but due to the caudal position deep within the retrobulbar space and level with the sphenoid bone, sampling might not be feasible, but by complete exenteration of the right orbit. The chances of palliative radiation therapy might be discussed with oncologist.

SPECIES

Canine

BREED

Pit Bull Terrier

SEX

FS

AGE

5

INTERPRETED BY

Sebastian Schaub, DVM
Dr. med. vet. DipECVDI

HOSPITAL NAME

Advanced Animal
Imaging

REFERRING VET

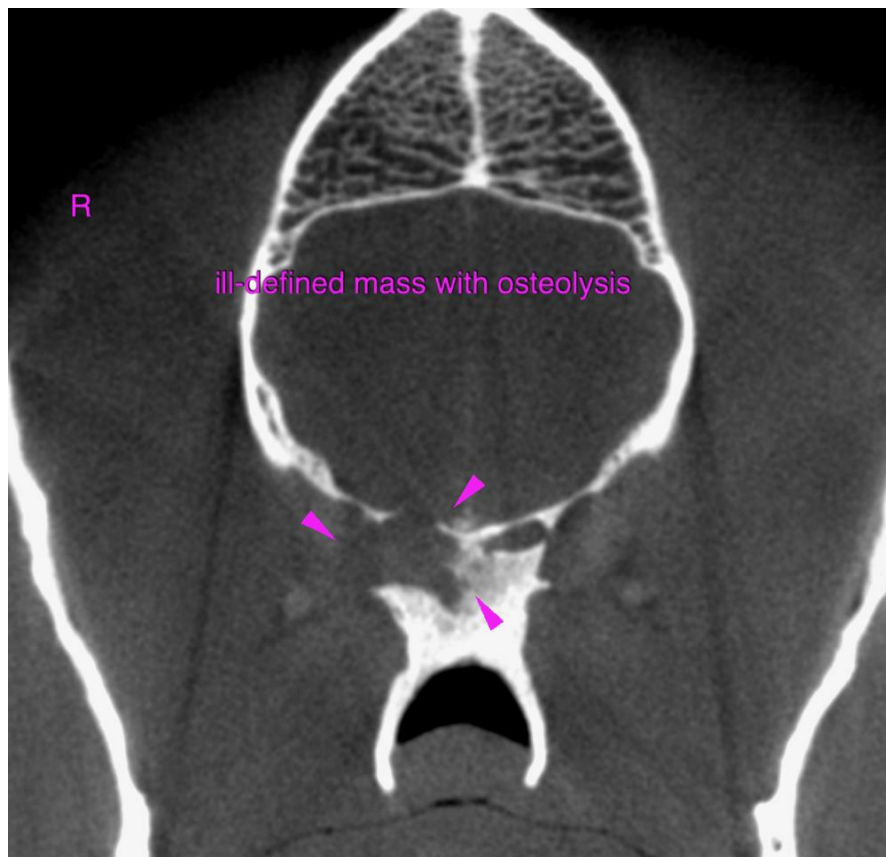
Blair Hollowell, DVM

INVOICE

50467

DATE

2-21-22



The information and recommendations provided are based on the images presented by the referring veterinarian/sonographer. No evaluation can be communicated regarding pathology that was not visible in the image/video clips provided.

Thank you for this referral. If the clinical or image interpretation does not parallel your findings or if I can be of any further assistance please contact me.

Sebastian Schaub, Sebastian Schaub, DVM, Dr. med. vet. DipECVDI
sebast.schaub@gmail.com