



PATIENT

Boss Heaton

PRESENTING CLINICAL SIGNS

Pet presented for dental cleaning; Imaging sent for evaluation of dental health & bone structure.

SPECIES

Canine

COMPUTED TOMOGRAPHY OF THE SKULL

A high resolution plain CT study of the skull is provided for review.

BREED

Boston Terrier

COMPUTED TOMOGRAPHIC FINDINGS

The tooth elements triadan 109, 110, 209, 305, 306, 311, 405, 408 and 411 are absent. Triadan 108 presents with a lamellar fracture. The crown of triadan 108 presents a lamellar fracture in the buccal aspect, exposing the pulp cavity to the dental surface. The periodontal space of the distal root is moderately widened. The palatine root of triadan 108 presents a transverse fracture in the transition between the crown and the root. The crown of triadan 306&408 is absent and retained tooth roots are seen within the alveolar crest. Triadan 308 presents with multiple lytic lesions of the crown. All canine teeth present evidence of mild periodontal disease.

SEX

MN

The nasal cavity presents the expected aerated spaces between thin & even conchae and turbinates with smooth mucosal lining.

AGE

8 Years

Both temporomandibular joints present congruent joint spaces with even subchondral bone surfaces and are considered within normal limits.

INTERPRETED BY

Sebastian Schaub, DVM
Dr. med. vet. DipECVDI

Both tympanic bullae are filled with soft tissue attenuating material. The external ear canals are within normal limits.

COMPUTED TOMOGRAPHIC DIAGNOSIS

HOSPITAL NAME

Cranberry Holistic
Pet Care

- Complicated lamellar dental fracture 108 and periodontal abscess formation, fractured palatine root
- Dental resorptive lesions 308
- Retained tooth roots 306&408
- Mild periodontal disease canine teeth
- Multiple absent teeth
- Bilateral otitis media, suspect primary secretory

REFERRING VET

Cynthia Maro

INTERPRETATION OF THE FINDINGS & FURTHER RECOMMENDATIONS

A complete dental workup has already been performed, regarding the history.

INVOICE

50459

DATE

2-21-22



PATIENT

Boss Heaton

SPECIES

Canine

BREED

Boston Terrier

SEX

MN

AGE

8 Years

INTERPRETED BY

Sebastian Schaub, DVM
Dr. med. vet. DipECVDI

HOSPITAL NAME

Cranberry Holistic
Pet Care

REFERRING VET

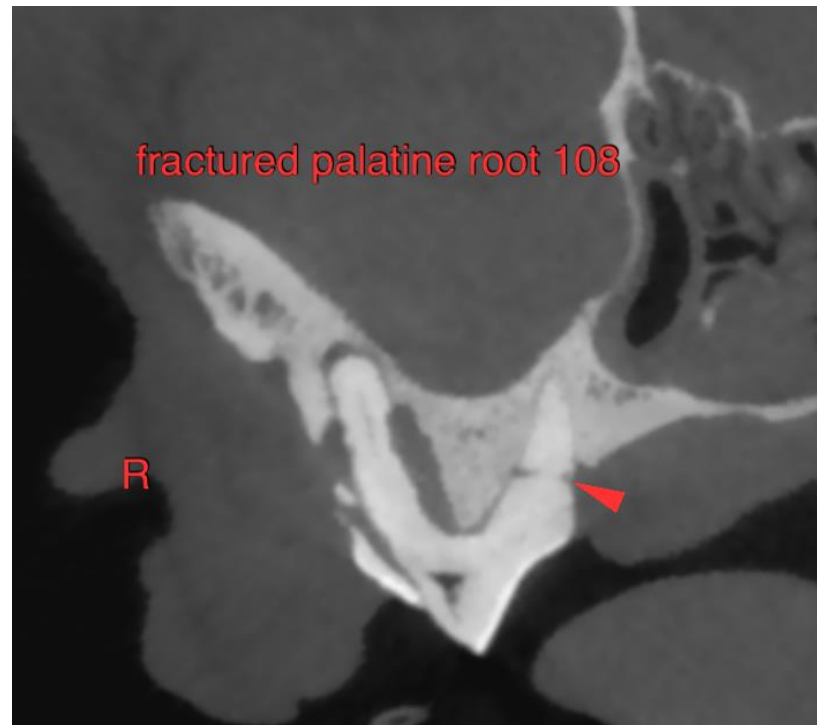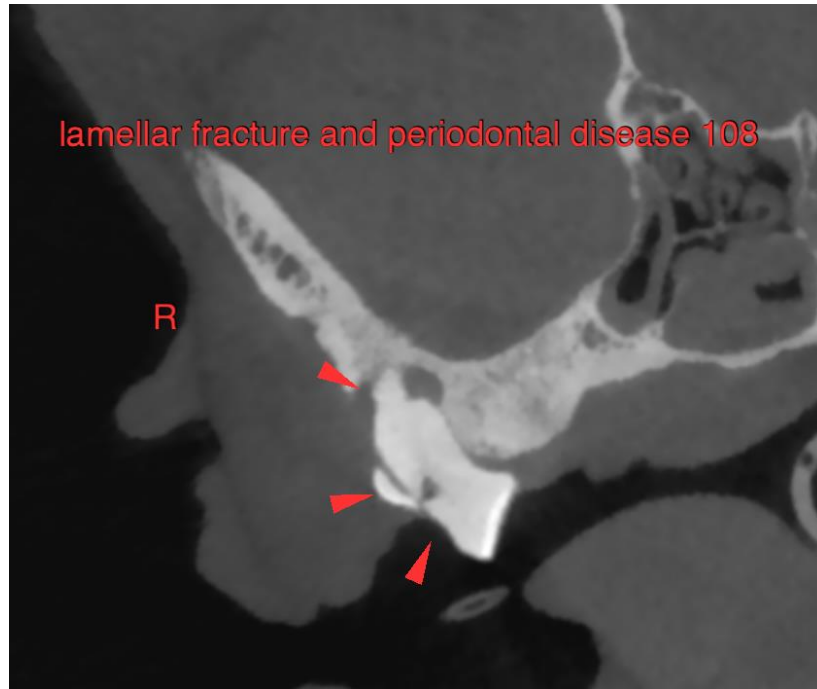
Cynthia Maro

INVOICE

50459

DATE

2-21-22





PATIENT

Boss Heaton

SPECIES

Canine

BREED

Boston Terrier

SEX

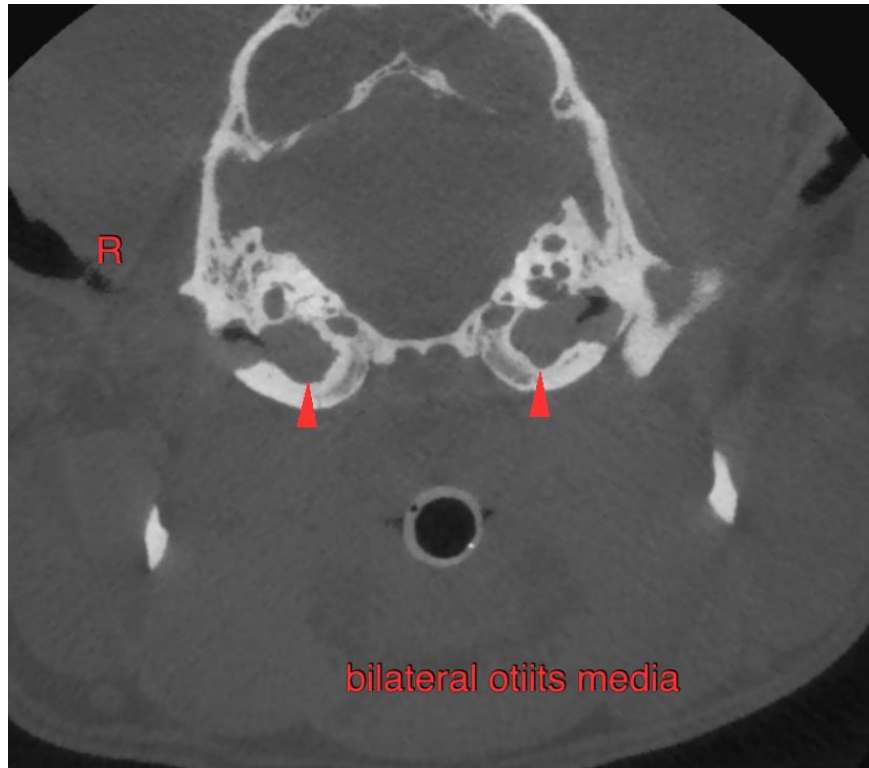
MN

AGE

8 Years

INTERPRETED BY

Sebastian Schaub, DVM
Dr. med. vet. DipECVDI



HOSPITAL NAME

Cranberry Holistic
Pet Care

REFERRING VET

Cynthia Maro

INVOICE

50459

DATE

2-21-22

The information and recommendations provided are based on the images presented by the referring veterinarian/sonographer. No evaluation can be communicated regarding pathology that was not visible in the image/video clips provided.

Thank you for this referral. If the clinical or image interpretation does not parallel your findings or if I can be of any further assistance please contact me.

Sebastian Schaub, Sebastian Schaub, DVM, Dr. med. vet. DipECVDI
sebast.schaub@gmail.com