

**PATIENT**

Bella Halko

PRESENTING CLINICAL SIGNS

Sudden onset of right hind lameness 2/8/22 following jumping. Pet has hx of MPL, but can't be elicited at this time. Also no palpable AACL injury.
Abnormal PE/Chem/CBC/UA Results: ALP=331; Lipase=1010; Chol=356; Alb=4.0 CBC--WN
UA: 3+ Proteinuria; 1+ struvites; pH=8.0; USpG=1.044

SPECIES

Canine

RADIOGRAPHIC STUDY OF THE PELVIS AND STIFLE JOINTS

Radiographs of the pelvis and right stifle joint in two imaging planes are provided for review.

BREED

Yorkie X

RADIOGRAPHIC FINDINGS

The osseous and surrounding soft tissue structures of the pelvis are within normal limits. The joint space of the coxofemoral joints is congruent.

SEX

Female Spayed

Both stifle joints present moderate osteophyte new bone formation. The patella of the stifle joints is superimposed on the medial femoral condyle. The right stifle joint presents a moderate intracapsular soft tissue swelling. There is possible mild cranial subluxation of the tibia.

AGE

12

RADIOGRAPHIC DIAGNOSIS

- Degenerative osteoarthritis stifle joints bilaterally
- Moderate articular swelling right stifle joint
- Possible cranial subluxation right stifle joint
- Suspect bilateral medial patellar luxation

INTERPRETED BY

Sebastian Schaub, DVM
Dr. med. vet. DipECVDI

INTERPRETATION OF THE FINDINGS & FURTHER RECOMMENDATIONS

There is evidence of bilateral degenerative joint disease of the stifle joints and joint effusion of the right stifle joint. Although the radiograph of the right stifle joint is not in a 90° flexed position, there is possible cranial subluxation of the right tibia, concerning for failure of the cranial cruciate ligament. Due to the age of the patient, the medial patellar luxation is considered as an incidental finding. Acute on chronic disease might be a consideration as well.

Consider testing if a positive drawer sign or tibial compression test under general anesthesia is present.

HOSPITAL NAME

Long Valley Animal
Hospital

REFERRING VET

Russell Earl

INVOICE

50458

DATE

2-21-22



PATIENT

Bella Halko

SPECIES

Canine

BREED

Yorkie X

SEX

Female Spayed

AGE

12

INTERPRETED BY

Sebastian Schaub, DVM
Dr. med. vet. DipECVDI

HOSPITAL NAME

Long Valley Animal
Hospital

REFERRING VET

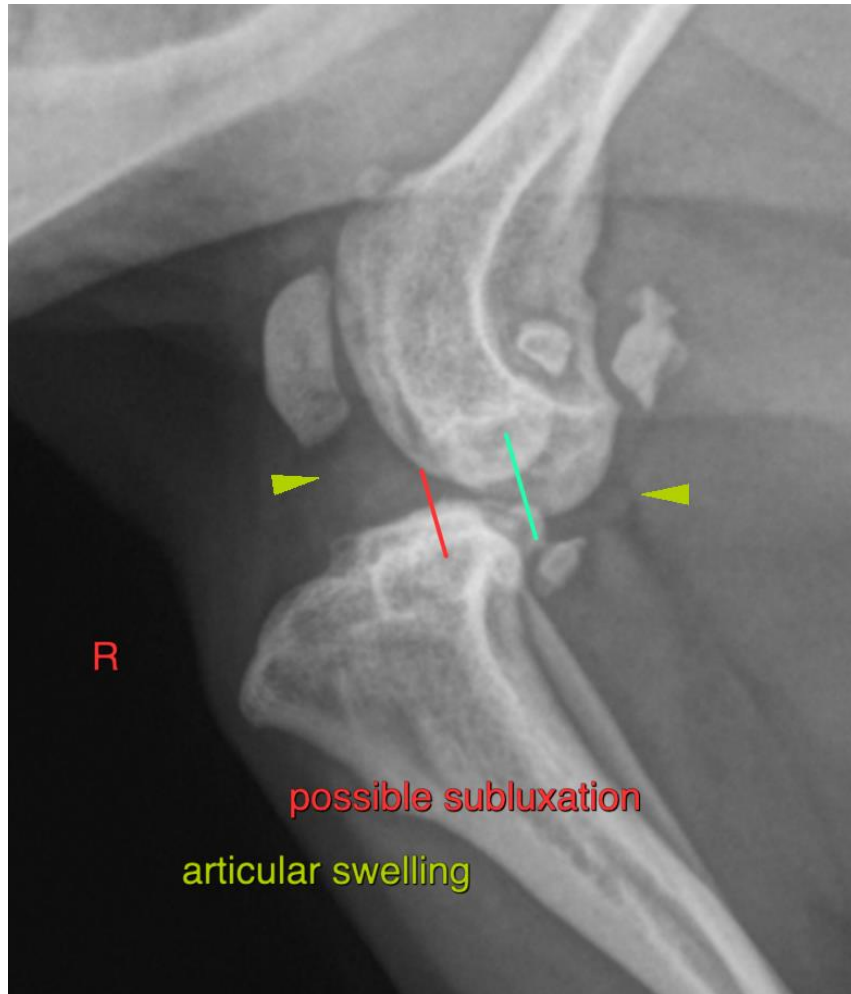
Russell Earl

INVOICE

50458

DATE

2-21-22



The information and recommendations provided are based on the images presented by the referring veterinarian/sonographer. No evaluation can be communicated regarding pathology that was not visible in the image/video clips provided.

Thank you for this referral. If the clinical or image interpretation does not parallel your findings or if I can be of any further assistance please contact me.

Sebastian Schaub, Sebastian Schaub, DVM, Dr. med. vet. DipECVDI
sebast.schaub@gmail.com