



PATIENT

Courage Loving
Touch Rescue

PRESENTING CLINICAL SIGNS

HERE FOR MASS REMOVE

RADIOGRAPHIC STUDY OF THE THORAX

Radiographs of the thorax in three imaging planes are provided for review.

SPECIES

K9

RADIOGRAPHIC FINDINGS

The surrounding bony structures are within normal limits.

BREED

Pitbull

At the caudoventral aspect of the thoracic wall, ventral to the xiphoid process, a roundish, soft tissue mass is noted, measuring 9 cm in size.

SEX

Male

The cranial mediastinum presents the expected soft tissue opacity. The mediastinal width is less than twice the width of the vertebral column at the same level.

AGE

5 Years

The bronchial tree presents with thin walls and tapers uniformly towards the periphery as expected.

INTERPRETED BY

Sebastian Schaub, DVM
Dr. med. vet. DipECVDI

The lung parenchyma presents the expected architecture and opacity; the intrapulmonary vascular branching is seen up to the third order lung vessels.

The diaphragm is well delineated with even surface and the expected mild cranial bulging of the diaphragmatic cupola.

RADIOGRAPHIC DIAGNOSIS

- History of (pedunculated) cutaneous soft tissue mass caudoventral thoracic wall

HOSPITAL NAME

Animal Surgical
Center

INTERPRETATION OF THE FINDINGS & FURTHER RECOMMENDATIONS

The radiographic study is negative for pulmonary metastatic disease.

REFERRING VET

Animal Care Centers
of NYC

INVOICE

56841

DATE

2-20-23



PATIENT

Courage Loving
Touch Rescue

SPECIES

K9

BREED

Pitbull

SEX

Male

AGE

5 Years

INTERPRETED BY

Sebastian Schaub, DVM
Dr. med. vet. DipECVDI

HOSPITAL NAME

Animal Surgical
Center

REFERRING VET

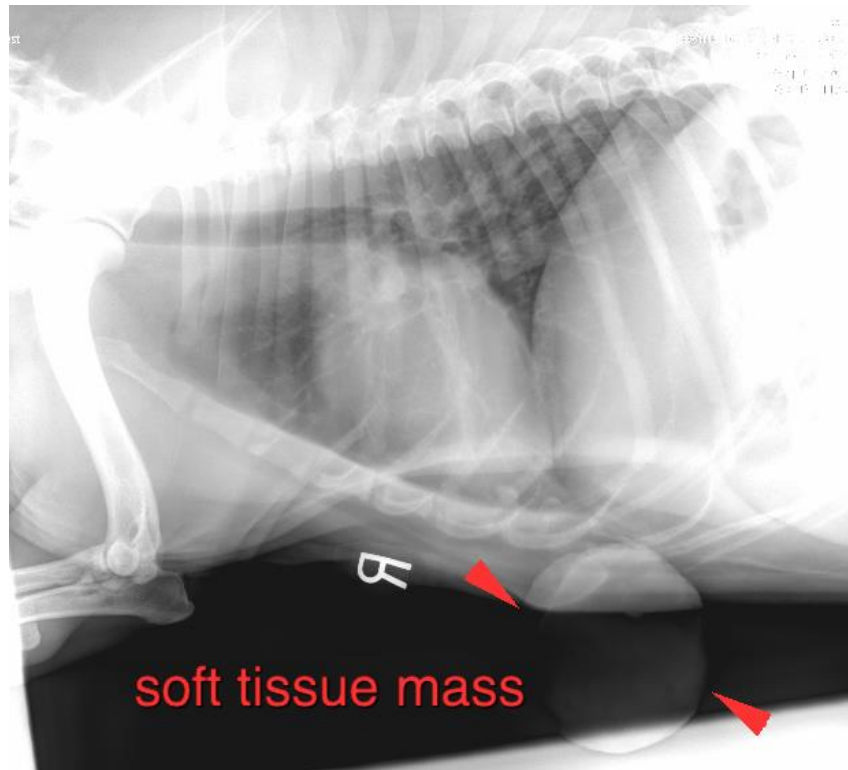
Animal Care Centers
of NYC

INVOICE

56841

DATE

2-20-23



The information and recommendations provided are based on the images presented by the referring veterinarian/sonographer. No evaluation can be communicated regarding pathology that was not visible in the image/video clips provided.

Thank you for this referral. If the clinical or image interpretation does not parallel your findings or if I can be of any further assistance please contact me.

Sebastian Schaub, Sebastian Schaub, DVM, Dr. med. vet. DipECVDI
sebast.schaub@gmail.com