



PATIENT

Brutus Casanova

SPECIES

Canine

BREED

Shih Tzu

SEX

Intact Male

AGE

7Y, 8M

WEIGHT

26lbs

INTERPRETED BY

Sebastian Schaub, DVM
Dr. med. vet.
DipECVDI

IMAGING PERFORMED BY

GC/MF

HOSPITAL NAME

The Pet Hospital of
Stratford

REFERRING VET

Dr. Claudia Giuliani,
DVM

INVOICE

73557

DATE

2-2-26

PRESENTING CLINICAL SIGNS

Brutus presents for limping on left hind leg. Owner stated that it started about two days ago and seems to be getting worse as it gets colder. He is not on any joint supplements, and has a history of arthritis in his front legs and history of possible IVDD. He is doing well otherwise. On PE, Brutus yelped when his left hind was extended. Luxating patella felt on this leg.

RADIOGRAPHIC STUDY OF THE PELVIS AND STIFLE JOINTS

Radiographs of the pelvis and stifle joints in orthogonal image planes are provided for review.

RADIOGRAPHIC FINDINGS

The osseous and surrounding soft tissue structures of the pelvis are within normal limits. Both coxofemoral joints present smooth osseous margins and congruent joint spaces.

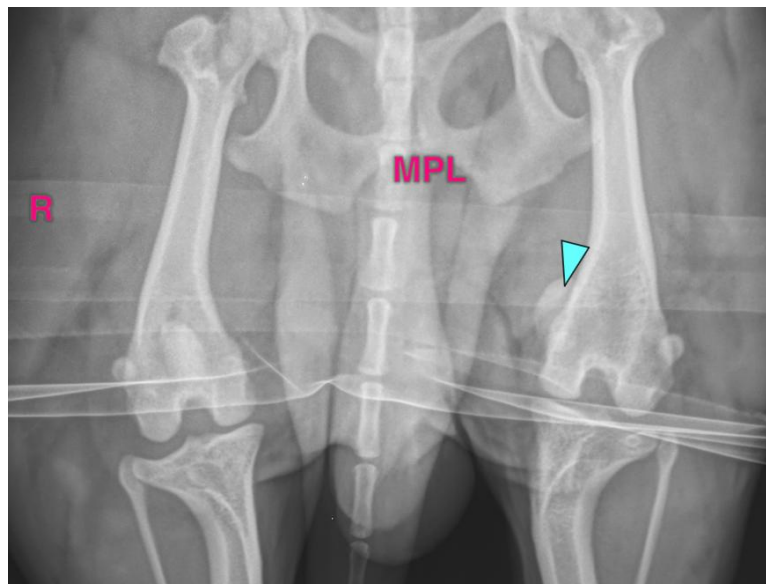
The patella of the left stifle joint is located at the craniomedial aspect of the medial femoral condyle. Both stifle joints present smooth margins of the periarticular bones and no evidence of an intracapsular soft tissue swelling.

RADIOGRAPHIC DIAGNOSIS

- Left sided medial patellar luxation
- Normal right stifle joint
- Normal pelvis

INTERPRETATION OF THE FINDINGS & FURTHER RECOMMENDATIONS

The main finding is the left sided medial patellar luxation, although the clinical relevance is unclear since the patellar luxation has likely been present for the patient's entire life but in case of traumatic patellar luxation. Check clinically for instability of the left stifle joint, suggestive for pathology of the cruciate ligament, as well.





PATIENT

Brutus Casanova

SPECIES

Canine

BREED

Shih Tzu

SEX

Intact Male

AGE

7Y, 8M

WEIGHT

26lbs

INTERPRETED BY

Sebastian Schaub, DVM
Dr. med. vet.
DipECVDI

IMAGING PERFORMED BY

GC/MF

HOSPITAL NAME

The Pet Hospital of
Stratford

REFERRING VET

Dr. Claudia Giuliani,
DVM

INVOICE

73557

DATE

2-2-26

The information and recommendations provided are based on the images presented by the referring veterinarian/sonographer. No evaluation can be communicated regarding pathology that was not visible in the image/video clips provided.

Thank you for this referral. If the clinical or image interpretation does not parallel your findings or if I can be of any further assistance please contact me.

Sebastian Schaub, Sebastian Schaub, DVM, Dr. med. vet. DipECVDI
info@sonopath.com