



PATIENT PRESENTING CLINICAL SIGNS

Lola Beeler
SPECIES Canine
BREED Chihuahua
SEX Spayed Female
AGE 13 Years

PRESENTED FOR: Annual, coughing, scooting, and scratching ears. **REPORTED SYMPTOM:** Owner reports history of a heart murmur. Cough/hack sometimes. Cough is inconsistent. Happens sometimes when sleeping or running. Some days not at all. Has been doing it for years. She reverse sneezes sometimes. **VITALS:** 7.04 pounds Temperature: 101.9 (normal range is 99.5 F- 102.0 F) Heart Rate: 70 bpm (normal is 70-80) Respiratory Rate: 60 bpm **EXCITED** (normal is 15-25) Mucous Membrane Color: pink Capillary Refill Time: <2 **CURRENT MEDICATIONS:** Heargard Plus **EXAM FINDINGS:** Increased respiratory rate. No murmur is auscultated today, however the heart and lung sounds are more difficult to hear on auscultation than is expected. Dental disease with loose 101. Bilateral cataracts. Lacks pupillary light reflexes, however still has dazzle and menace reflexes are present. Grade III Medial Patella Luxation (Bilaterally) Pododermatitis. **LAB RESULTS:** CBC reveals a mild leukopenia. Manual slide evaluation pending. Chemistry panel reveals slightly elevated alk phos and glucose. Urinalysis results reveal uro 2, pH 5.0, with specific gravity of 1.025. **ASSESSMENT AND PLAN:** Manual slide results pending.

RADIOGRAPHIC STUDY OF THE THORAX

Radiographs of the thorax in three imaging planes are provided for review.

RADIOGRAPHIC FINDINGS

Moderate dorsal bending of the mid segment of the sternum is seen.
 The extrathoracic soft tissues present homogeneous without abnormalities.

INTERPRETED BY

Sebastian Schaub, DVM
 Dr. med. vet. DipECVDI

The heart is of normal size and shape, there is no evidence of cardiac chamber or vascular enlargement. The pulmonary vasculature is within normal limits.

The cranial mediastinum presents the expected soft tissue opacity. The mediastinal width is less than twice the width of the vertebral column at the same level.

HOSPITAL NAME

All Pets Medical Center

The trachea is normal in diameter and presents the anticipated course. The luminal outline of the trachea is smooth.

The bronchial tree presents with thin walls and tapers uniformly towards the periphery as expected.

REFERRING VET

Dr. Agnes Rupley

The lung parenchyma presents the expected architecture and a moderate ground glass opacification in the lateral views – due to expiration – in the VD view the lung parenchyma has the expected density and the intrapulmonary vascular branching is seen up to the third order lung vessels.

The diaphragm is well delineated with even surface and the expected mild cranial bulging of the diaphragmatic cupola.

INVOICE

56562

RADIOGRAPHIC DIAGNOSIS

- Pecten excavatum

DATE

2-2-23

INTERPRETATION OF THE FINDINGS & FURTHER RECOMMENDATIONS

The radiographic study of the thorax presents without abnormalities explaining the history of cough. However, negative thoracic radiographs do not rule out possible inflammatory lower



PATIENT airway disease.

Lola Beeler

SPECIES

Canine

BREED

Chihuahua

SEX

Spayed Female

AGE

13 Years

INTERPRETED BY

Sebastian Schaub, DVM
Dr. med. vet. DipECVDI

HOSPITAL NAME

All Pets Medical
Center

REFERRING VET

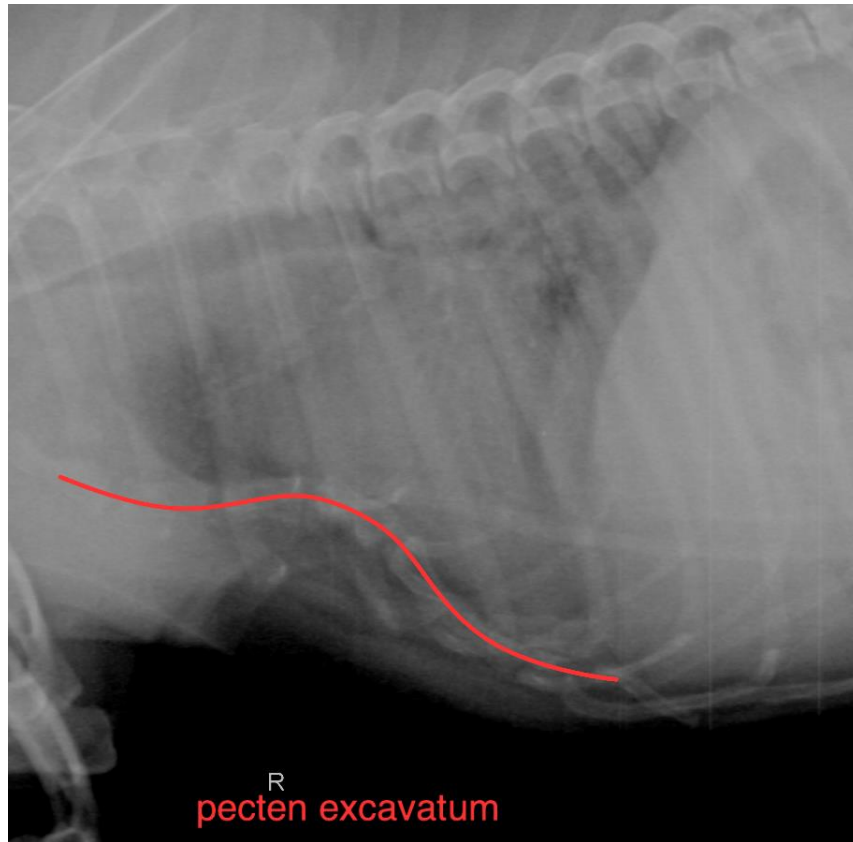
Dr. Agnes Rupley

INVOICE

56562

DATE

2-2-23



The information and recommendations provided are based on the images presented by the referring veterinarian/sonographer. No evaluation can be communicated regarding pathology that was not visible in the image/video clips provided.

Thank you for this referral. If the clinical or image interpretation does not parallel your findings or if I can be of any further assistance please contact me.

Sebastian Schaub, Sebastian Schaub, DVM, Dr. med. vet. DipECVDI
sebast.schaub@gmail.com