



PATIENT

Timmy Evans

PRESENTING CLINICAL SIGNS

1/14/22 Swelling noted on left side of head, not painful with palpation, but painful if mouth opened all the way (vocalized). No change in appetite or attitude. Trial of Rimadyl and Clavamox. Ultrasound performed 1/17/22. 2 pockets of fluid noted. Aspirated bloody fluid, submitted for cytology to Idexx, diagnosis, hemorrhagic inflammation. Started on Prednisone 30 Mg BID with appropriate gastro protectants: Carafate and famotidine. Repeat ultrasound 1/18/22 pockets of fluid resolving, swelling moderately decreased and less painful with opening mouth. Started Prednisone taper on 1/22/22. 1/26/22 Decreased to 15 mg SID and swelling and pain returned so increased Prednisone to 20 MG BID. Rule outs: Neoplasia; Nerve sheath tumor

SPECIES

Canine

BREED

Labrador Retriever
Mix

COMPUTED TOMOGRAPHY OF THE SKULL

A high resolution pre- and post-contrast CT study of the skull is provided for review.

COMPUTED TOMOGRAPHIC FINDINGS

SEX

The pictured parts of the dentition are complete and unremarkable in all jaw quadrants.

MN

In the caudal aspect of the left temporal muscle, starting level with the coronoid process of the left mandible and extending caudally up to the level of the occipital bone, a post contrast heterogeneous contrast enhancing, ill-defined mass, measuring 6.2 x 3.9 x 7.9 cm in size.

AGE

11

The nasal cavity presents the expected aerated spaces between thin & even conchae and turbinates with smooth mucosal lining.

INTERPRETED BY

Sebastian Schaub, DVM
Dr. med. vet. DipECVDI

Both temporomandibular joints present congruent joint spaces with even subchondral bone surfaces and are considered within normal limits.

Both tympanic bullae are aerated, the mucosal lining is not seen, the bony wall is smooth and thin. The external ear canals are within normal limits.

HOSPITAL NAME

Advanced Animal
Imaging

The brain presents no deviation from normal anatomy and symmetry. The brain parenchyma is homogeneous and within normal limits for attenuation and distribution of contrast enhancement. The ventricular system is non-dilated and symmetric.

REFERRING VET

Blair Hollowell, DVM

The submandibular and medial retropharyngeal lymph nodes are small and elongated with a normal short-to-long-axis-ratio is < 0.5, the attenuation and contrast enhancement pattern is uniform.

COMPUTED TOMOGRAPHIC DIAGNOSIS

INVOICE

50041

- Intramuscular mass left temporal muscle

INTERPRETATION OF THE FINDINGS & FURTHER RECOMMENDATIONS

DATE

2-2-22

The CT study is highly suggestive for an intramuscular neoplasia in the left temporal muscle – such as hemangiosarcoma, rhabdomyosarcoma, fibrosarcoma, other. Biopsy can be used as advanced diagnostic test to confirm the diagnosis. Based on the results of the advanced diagnostic tests, the chances of radiation therapy or surgical options should be discussed with



PATIENT

Timmy Evans

oncologist. Although there is no evidence of osteolytic lesions, the mass is in contact with the occipital bone and proximal margin of the coronoid process of the left mandible.

Consider full tumor staging.

SPECIES

Canine

BREED

Labrador Retriever
Mix

SEX

MN

AGE

11

INTERPRETED BY

Sebastian Schaub, DVM
Dr. med. vet. DipECVDI

HOSPITAL NAME

Advanced Animal
Imaging

REFERRING VET

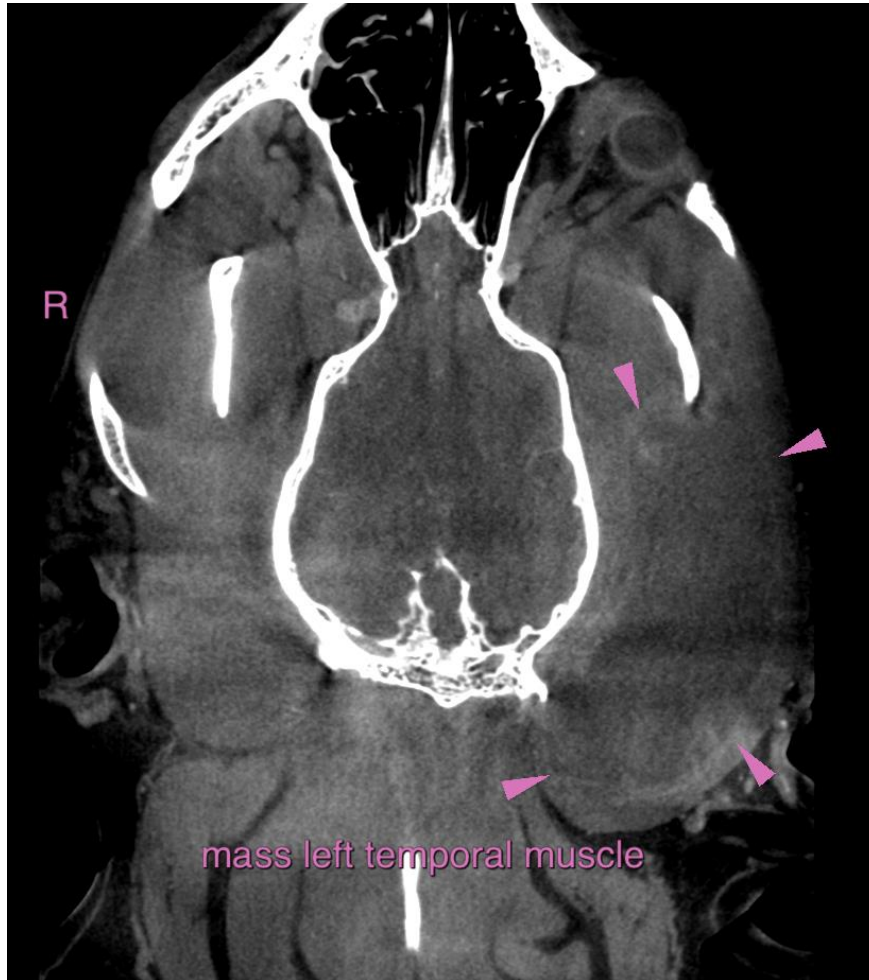
Blair Hollowell, DVM

INVOICE

50041

DATE

2-2-22





PATIENT

Timmy Evans

SPECIES

Canine

BREED

Labrador Retriever
Mix

SEX

MN

AGE

11

INTERPRETED BY

Sebastian Schaub, DVM
Dr. med. vet. DipECVDI

HOSPITAL NAME

Advanced Animal
Imaging

REFERRING VET

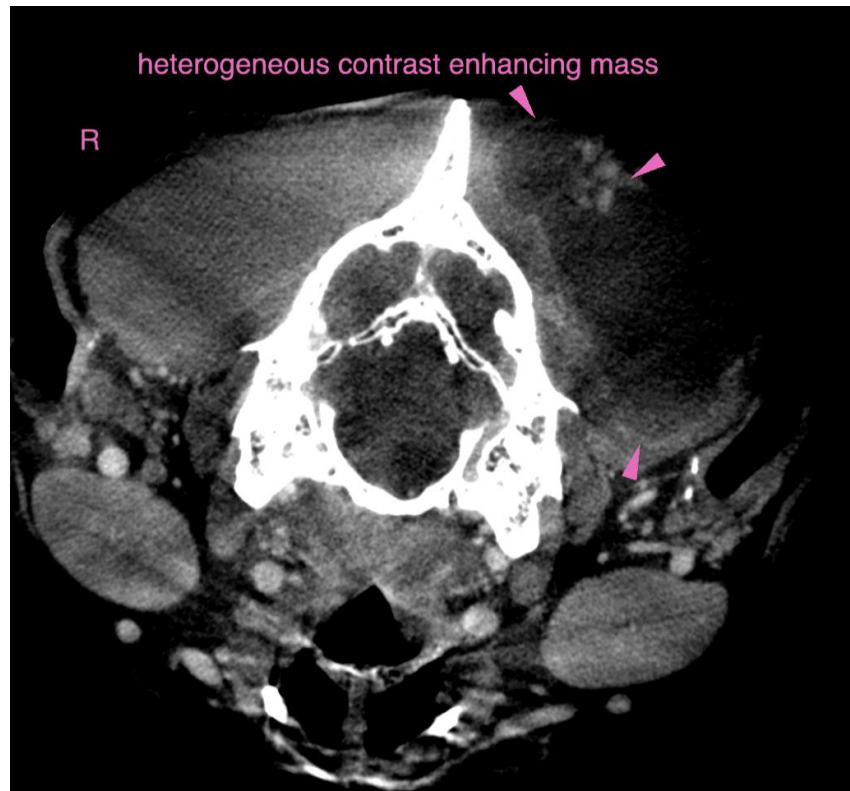
Blair Hollowell, DVM

INVOICE

50041

DATE

2-2-22



The information and recommendations provided are based on the images presented by the referring veterinarian/sonographer. No evaluation can be communicated regarding pathology that was not visible in the image/video clips provided.

Thank you for this referral. If the clinical or image interpretation does not parallel your findings or if I can be of any further assistance please contact me.

Sebastian Schaub, Sebastian Schaub, DVM, Dr. med. vet. DipECVDI
sebast.schaub@gmail.com