



**PATIENT**

Jack Young

**PRESENTING CLINICAL SIGNS**

Presented for COHAT with extractions. Tooth resorption lesions on 108, 207, 208, and 208. Those were extracted.

**SPECIES**

Feline

**COMPUTED TOMOGRAPHY OF THE SKULL**

A high resolution pre- and post-contrast CT study of the skull is provided for review.

**BREED**

DSH

**COMPUTED TOMOGRAPHIC FINDINGS**

The tooth elements 307&407 are absent. Triadan 108, 207, 208, 309 present resorptive lesions of the crown. Advanced resorption and ankylosis of the distal root of triadan 207 is noted. A moderate amount of mineral attenuating material is attached to the crowns of multiple premolar teeth

**SEX**

MN

The nasal cavity presents the expected aerated spaces between thin & even conchae and turbinates with smooth mucosal lining.

**AGE**

9 Years

Both temporomandibular joints present congruent joint spaces with even subchondral bone surfaces and are considered within normal limits.

Both tympanic bullae are aerated, the mucosal lining is not seen, the bony wall is smooth and thin. The external ear canals are within normal limits.

**INTERPRETED BY**

Sebastian Schaub, DVM  
Dr. med. vet. DipECVDI

**COMPUTED TOMOGRAPHIC DIAGNOSIS**

- Dental resorptive lesions 108, 207, 208, 309 with ankylosis of the distal root of triadan 207
- Dental tartar
- Absent triadan 307&407

**HOSPITAL NAME**

South Bay Animal  
Hospital & Pet Resort

**INTERPRETATION OF THE FINDINGS & FURTHER RECOMMENDATIONS**

There is evidence of resorptive lesions of multiple teeth. A complete dental workup with extraction of the affected teeth has already been performed.

**REFERRING VET**

Dr. Rupashree Rao

**INVOICE**

50048

**DATE**

2-2-22



**PATIENT**

Jack Young

**SPECIES**

Feline

**BREED**

DSH

**SEX**

MN

**AGE**

9 Years

**INTERPRETED BY**

Sebastian Schaub, DVM  
Dr. med. vet. DipECVDI

**HOSPITAL NAME**

South Bay Animal  
Hospital & Pet Resort

**REFERRING VET**

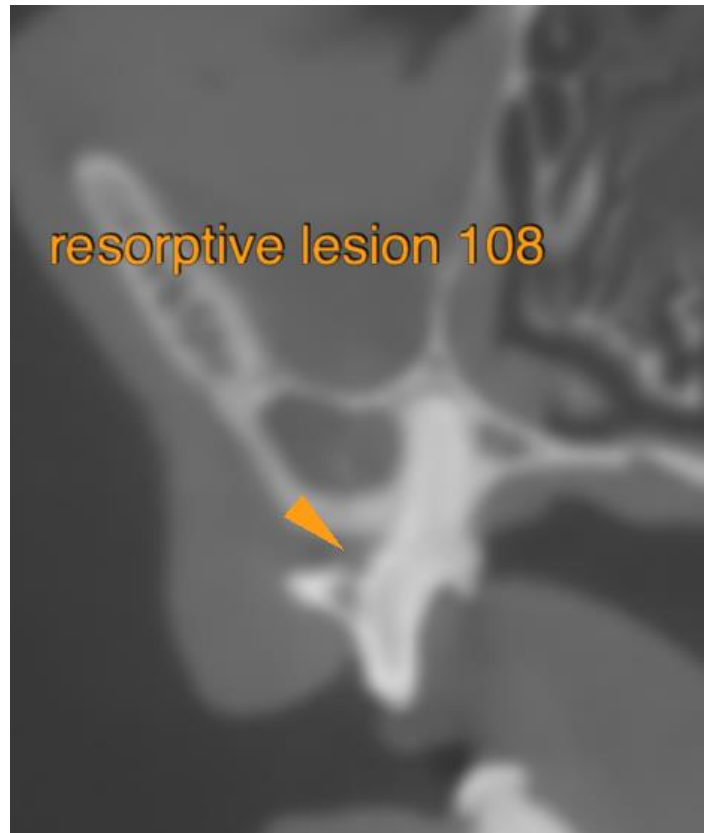
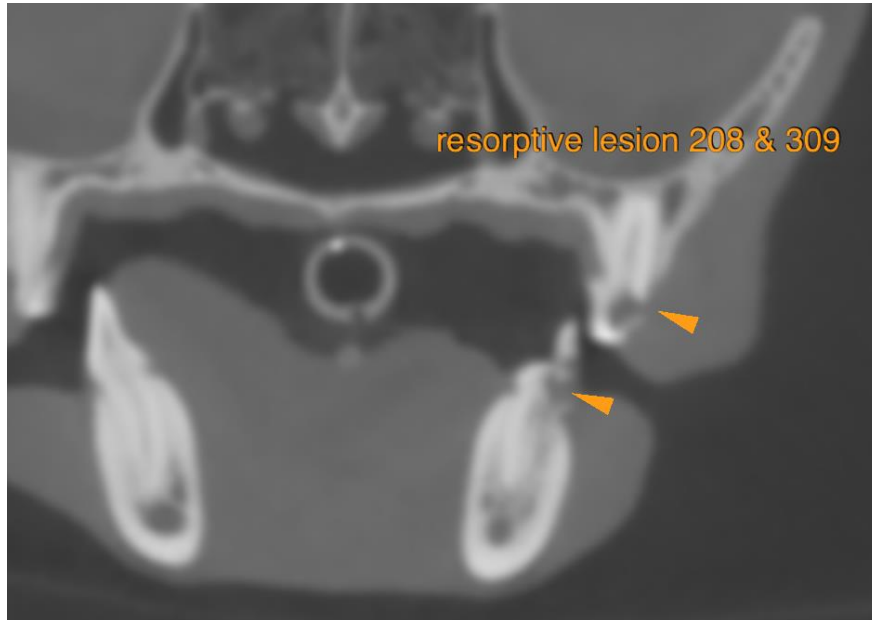
Dr. Rupashree Rao

**INVOICE**

50048

**DATE**

2-2-22





**PATIENT**

Jack Young

**SPECIES**

Feline

**BREED**

DSH

**SEX**

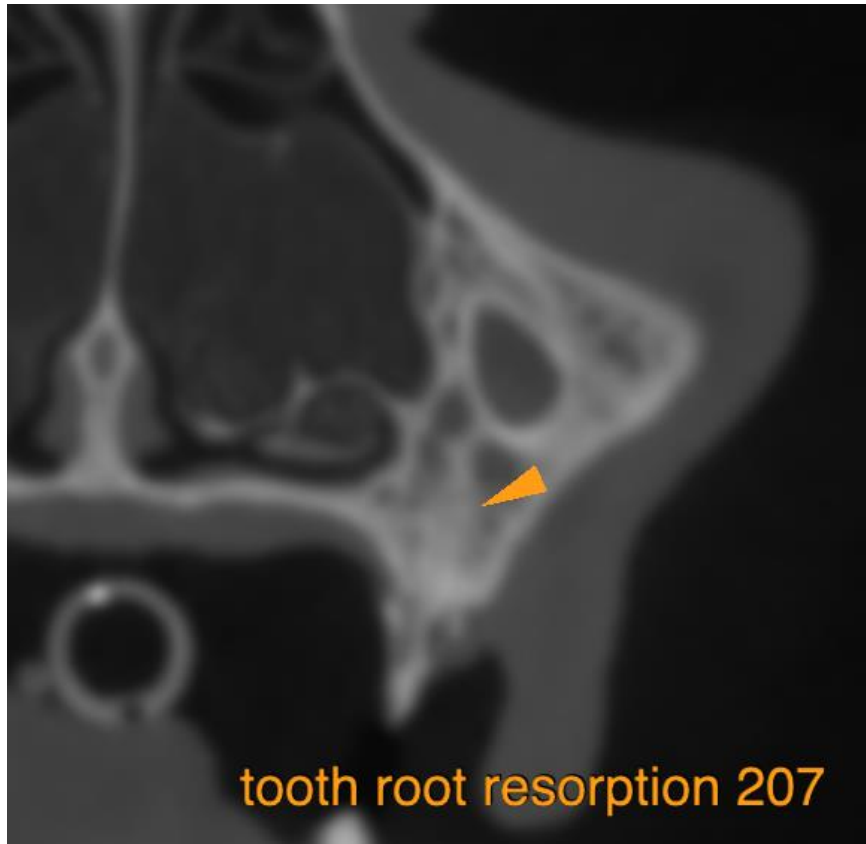
MN

**AGE**

9 Years

**INTERPRETED BY**

Sebastian Schaub, DVM  
Dr. med. vet. DipECVDI



tooth root resorption 207

**HOSPITAL NAME**

South Bay Animal  
Hospital & Pet Resort

**REFERRING VET**

Dr. Rupashree Rao

The information and recommendations provided are based on the images presented by the referring veterinarian/sonographer. No evaluation can be communicated regarding pathology that was not visible in the image/video clips provided.

Thank you for this referral. If the clinical or image interpretation does not parallel your findings or if I can be of any further assistance please contact me.

**Sebastian Schaub**, Sebastian Schaub, DVM, Dr. med. vet. DipECVDI  
sebast.schaub@gmail.com

**INVOICE**

50048

**DATE**

2-2-22