



PATIENT

Lalo Ortiz

SPECIES

Canine

BREED

Mix

SEX

Male

AGE

13Y

WEIGHT

10.5lbs

INTERPRETED BY

Sebastian Schaub, DVM
Dr. med. vet.
DipECVDI

IMAGING PERFORMED BY

Dario

HOSPITAL NAME

Animal Clinic of
Queens

REFERRING VET

Dr. Mandanini

INVOICE

73879

DATE

2-19-26

PRESENTING CLINICAL SIGNS

Pt had potential seizure like episode last week. Coughing and restless at night. Pt has 4/6 Heart Murmur.

RADIOGRAPHIC STUDY OF THE THORAX & ABDOMEN

A complete set of radiographs of the thorax and abdomen are provided for review.

RADIOGRAPHIC FINDINGS

Thorax

The surrounding bony structures are within normal limits.

The extrathoracic soft tissues present homogeneous without abnormalities.

The caudal contour of the cardiac silhouette is steep, and the caudal cardiac waist is lost. A wedge shaped soft tissue opacity is seen in the region of the left atrium along with a double opacity in the VD view. Mild splaying the main stem bronchi is appreciated. The pulmonary vasculature is within normal limits.

The cranial mediastinum presents the expected soft tissue opacity. The mediastinal width is less than twice the width of the vertebral column at the same level.

The trachea is normal in diameter and presents the anticipated course. The luminal outline of the trachea is smooth.

The bronchial tree presents with thin walls and tapers uniformly towards the periphery as expected.

The lung parenchyma presents the expected architecture and opacity; the intrapulmonary vascular branching is seen up to the third order lung vessels.

The diaphragm is well delineated with even surface and the expected mild cranial bulging of the diaphragmatic cupola.

Abdomen

The surrounding bony structures are within normal limits.

No abnormalities of the extraabdominal soft tissues are noted. The abdominal wall is smooth and thin.

The serosal detail is maintained throughout the peritoneal and retroperitoneal space.

The liver is appropriate in position, size and presents uniform opacity.

The splenic head is in the anticipated position and within normal limits for size and opacity. The splenic body and tail are considered normal for position, size, shape and opacity.

Both kidneys are seen and present with normal size, shape, delineation and opacity. The urinary bladder is in its anticipated position. No radiopaque calculi are noted throughout the upper and lower urinary tract.

The stomach is in its anticipated position and presents normal content.

The small intestinal loops are of even diameter and non-dilated, a small amount of gas is seen within the small intestinal loops and considered within normal limits.

The colon is seen in the expected position and presents with appropriate content.



PATIENT

Lalo Ortiz

SPECIES

Canine

BREED

Mix

SEX

Male

AGE

13Y

WEIGHT

10.5lbs

INTERPRETED BY

Sebastian Schaub, DVM
Dr. med. vet.
DipECVDI

IMAGING PERFORMED BY

Dario

HOSPITAL NAME

Animal Clinic of
Queens

REFERRING VET

Dr. Mandanini

INVOICE

73879

DATE

2-19-26

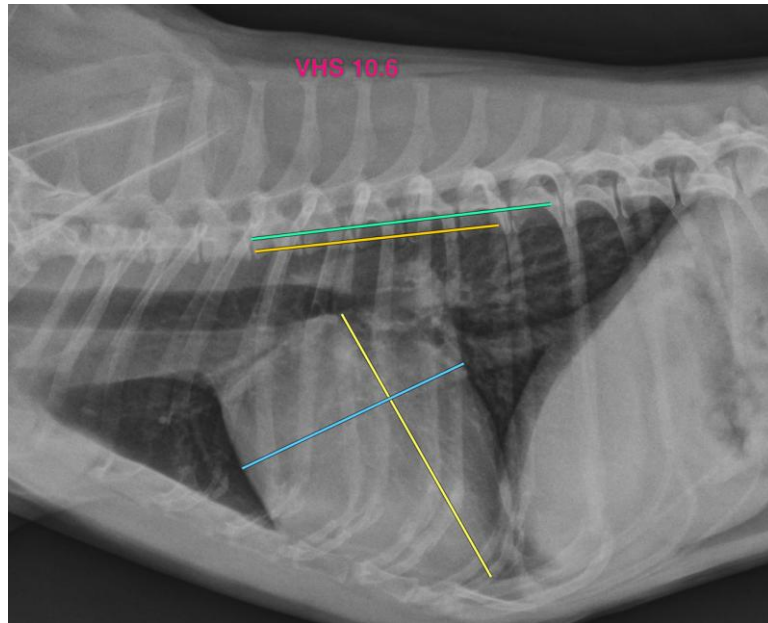
RADIOGRAPHIC DIAGNOSIS

- Left sided cardiomegaly without signs of decompensation
- Normal abdomen

INTERPRETATION OF THE FINDINGS & FURTHER RECOMMENDATIONS

The left sided cardiomegaly in combination with the heart murmur is most consistent with underlying mitral valve disease. A cardiac echo can be used for further assessment of cardiac chamber size and function.

No abnormalities are appreciated that do explain the described seizure activity. An ECG can be performed to rule out underlying arrhythmia.



The information and recommendations provided are based on the images presented by the referring veterinarian/sonographer. No evaluation can be communicated regarding pathology that was not visible in the image/video clips provided.

Thank you for this referral. If the clinical or image interpretation does not parallel your findings or if I can be of any further assistance please contact me.

Sebastian Schaub, Sebastian Schaub, DVM, Dr. med. vet. DipECVDI
info@sonopath.com